



6th Edition
INTERNATIONAL
CONGRESS OF
**REGENERATIVE
MEDICINE**



ORTHO REGEN
International Course

THE TREATMENT OF COMPLEX WOUNDS USING AUTOLOGOUS GRAFTS: CHANGING PARADIGMS

Eliud Garcia Duarte Junior – ES

Vascular Surgeon accredited by the Brazilian Medical Association (AMB)

Full Member of the Brazilian Society of Angiology and Vascular Surgery (SBACV)

President of SBACV-ES for 2021-2022 and 2022-2023

Financial Director of SBACV-ES

Coordinator of the Diabetic Foot Guideline at SBACV/AMB

Member of the Diabetic Foot Department at CFM (Federal Council of Medicine)

Coordinator of the Vascular Surgery Service at the State Emergency Hospital – São Lucas Hospital

Secretary Director of the Angiologists and Vascular Surgeons Cooperative of Espírito Santo –

CoopangioES

Teaching Preceptor in the Medicine Course at Vila Velha University – UVV/ES

Creator and Coordinator of A.D.F.S – Advanced Diabetic Foot Support Course

Associate Member of D-Foot International





SEFFICARE™


Regenerative Medicine

Wound treatment

Cellular techniques



Effectiveness of Stem Cell Therapy for Diabetic Foot Ulcers: A Systematic Review and GRADE Compliant Bootstrapped Meta-Analysis of Randomized Clinical Trials

Shiv Kumar Mudgal, PhD¹, Subodh Kumar, MD¹, Rakhi Gaur, PhD¹, Harminder Singh, MD¹, Dibyajyoti Saikia, MD², Saurabh Varshney, MS¹, Pratima Gupta, MD¹, Ashoo Grover, MD³, and Seshadri Reddy Varikasuvu, PhD¹ 

Abstract

Diabetic foot (DF) represents a severe complication of diabetes mellitus, imposing substantial psychological and economic burdens on affected individuals. This investigation sought to assess the therapeutic efficacy of stem cell interventions in the management of DF complications. A comprehensive systematic search across PubMed, Embase, CINAHL, Scopus, and the Cochrane library databases was conducted to identify pertinent studies for meta-analysis. Outcome measures encompassed ulcer or wound healing rates, amputation rates, angiogenesis, ankle-brachial index (ABI), and pain-free walking distance. Dichotomous outcomes were expressed as risk differences (RDs) with 95% confidence intervals (CIs), while continuous data were articulated as standardized mean differences (SMDs) with corresponding 95% CIs. Statistical analyses were executed using RevMan 5.3 and Open Meta, with bootstrapped meta-analysis conducted through OpenMEE software. A total of 20 studies, comprising 24 arms and involving 1304 participants, were incorporated into the meta-analysis. The findings revealed that stem cell therapy exhibited superior efficacy compared to conventional interventions in terms of ulcer or wound healing rate [RD=0.36 (0.28, 0.43)], pain-free walking distance [SMD=1.27 (0.89, 1.65)], ABI [SMD=0.61 (0.33, 0.88)], and new vessel development [RD=0.48 (0.23, 0.78)], while concurrently reducing the amputation rate significantly [RD=-0.19 (-0.25, -0.12)]. Furthermore, no statistically significant difference in adverse events was observed [RD -0.07 (-0.16, 0.02)]. The Grading of Recommendations, Assessment, Development, and Evaluation assessment indicated varying levels of evidence certainty, ranging from very low to moderate, for different outcomes. Bootstrapping analysis substantiated the precision of the results. The meta-analysis underscores the significant superiority of stem cell therapy over conventional approaches in treating DF complications. Future investigations should prioritize large-scale, randomized, double-blind, placebo-controlled, multicenter trials, incorporating rigorous long-term follow-up protocols. These studies are essential for elucidating the optimal cell types and therapeutic parameters that contribute to the most effective treatment strategies for DF management.

The International Journal of Lower Extremity Wounds
1–16
© The Author(s) 2024
Article reuse guidelines:
sagepub.com/journals-permissions
DOI: 10.1177/15347346241227530
journals.sagepub.com/home/ijl



Mudgal et al

9

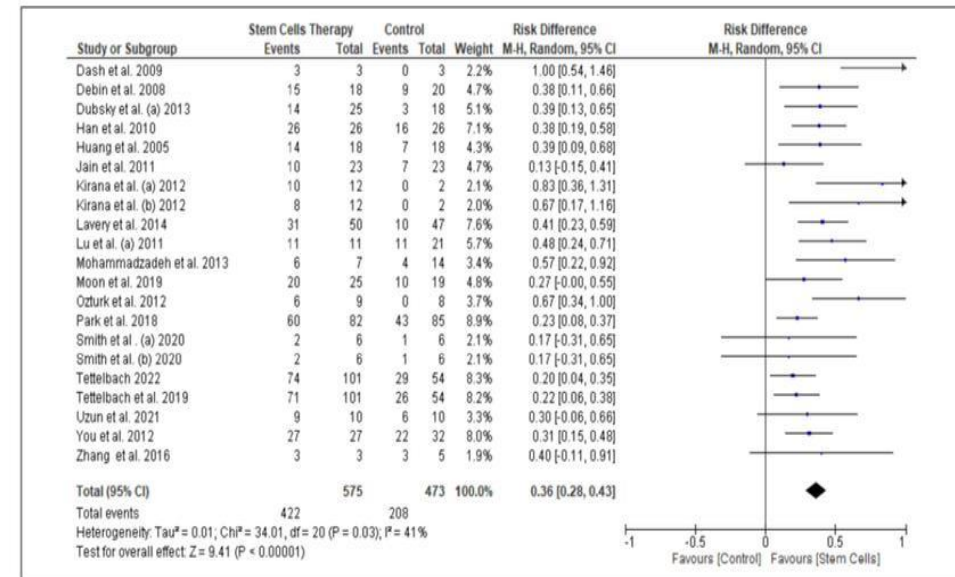


Figure 2. Forest plot showing the effect of stem cell therapy on ulcer healing rate.

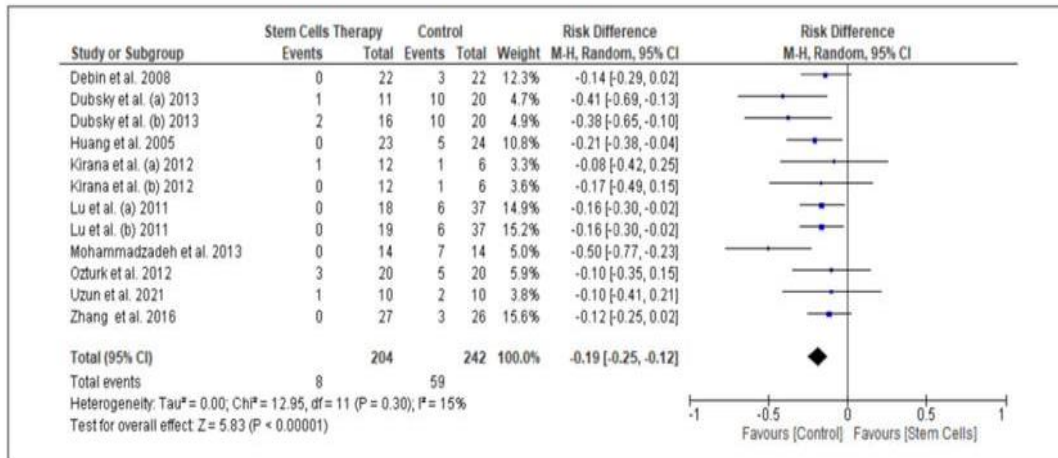


Figure 3. Forest plot showing the effect of stem cell therapy on amputation rate.

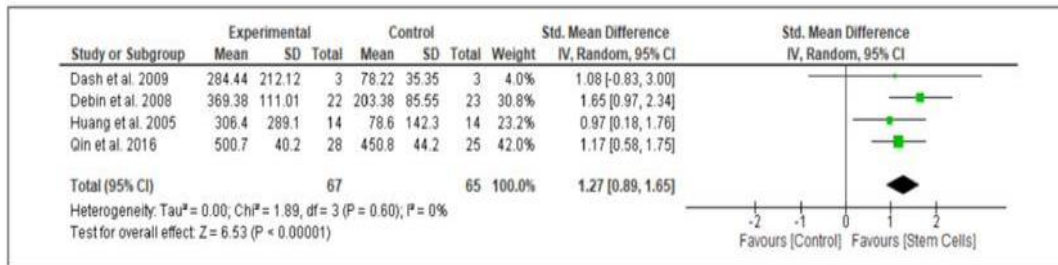


Figure 4. Forest plot showing the effect of stem cell therapy on pain-free walk.

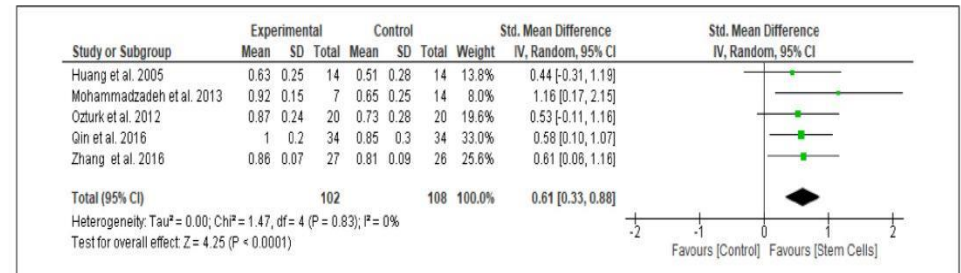


Figure 5. Forest plot showing the effect of stem cell therapy on ankle-brachial index.

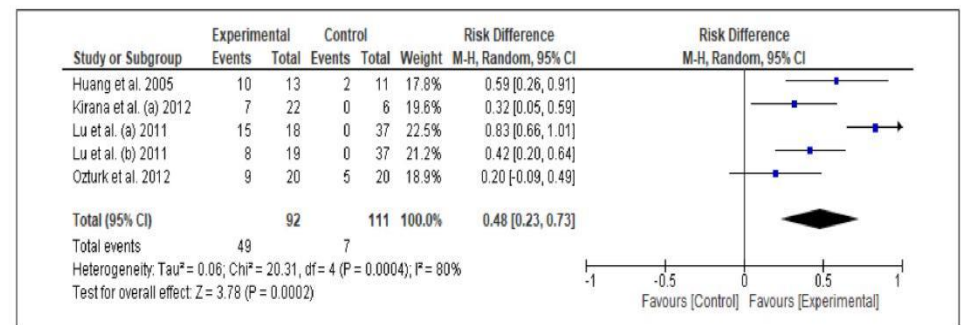


Figure 6. Forest plot showing the effect of stem cell therapy on new vessels development.

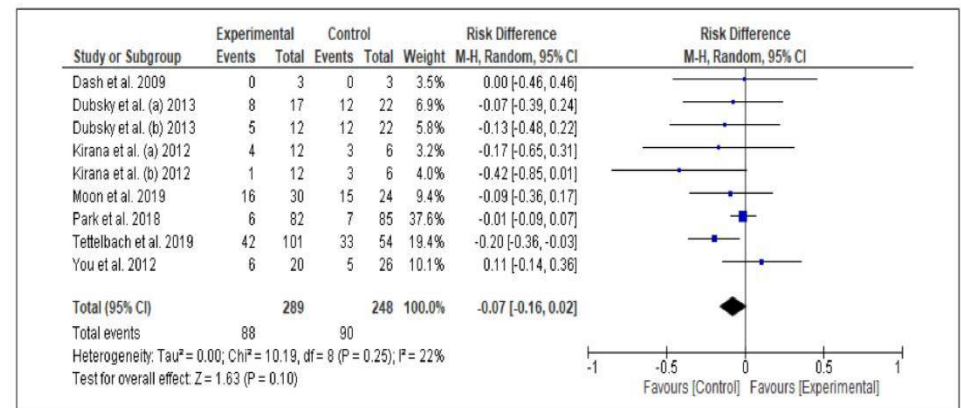


Figure 7. Forest plot showing the effect of stem cell therapy on adverse events.

Original Article

Effectiveness of Stem Cell Therapy for Diabetic Foot Ulcers: A Systematic Review and GRADE Compliant Bootstrapped Meta-Analysis of Randomized Clinical Trials

The International Journal of Lower Extremity Wounds
1-16
© The Author(s) 2024
Article reuse guidelines:
sagepub.com/journalsPermissions
DOI: 10.1177/1540319424127330
journals.sagepub.com/home/ijlw
Sage

ADJUVANT THERAPIES IN REFRACTORY ULCERS

- Special dressings
- Dermal Matrix
- Extracellular Matrix
- Hyperbaric Chamber
- Negative Pressure Therapies
- Shockwave Therapy
- Photobiomodulation - Low and High-Power Laser

REGENERATIVE MEDICINE

- Autologous Peripheral Blood Grafts
- Composite Grafts with Fat
- Use of Autologous Bone Marrow Aspirate (BMA)
- PRP (Platelet-Rich Plasma)
- PRF (Platelet-Rich Fibrin)

SOIL PREPARATION

Control of systemic chronic inflammation

Lifestyle

Diet

Control of obesity and metabolic syndrome, smoking, sedentary

Adequate sleep

Avoiding alcohol abuse

Control of chronic diseases

DIABETES/HYPERTENSION ADDRESSING THE CAUSE OF THE INJURY



CELLULAR TECHNIQUES

AUTOLOGOUS GRAFT

Peripheral blood

Bone marrow aspirate

Products derived from adipose tissue

STEM CELLS (SC)

Undifferentiated cells.

Undergo asymmetric division.

They can multiply in an undifferentiated manner, maintaining a reservoir of cells identical to the mother cell, or they can multiply, generating a specialized cell.

Example: Hematopoietic stem cells that give rise to hepatocytes.

PLASTICITY

PARACRINE EFFECT

ADULT STEM CELLS

Mesenchymal Stem Cells (MSCs)

Adipocytes

Bone Marrow

Skin

Hematopoietic Stem Cells (HSCs): Fibroblastoid

Bone Marrow Ability to form colonies (in vitro)

Colony-forming units

MSCs - PARACRINE EFFECT

BIOMOLECULES:

Immunomodulators

Inflammatory Regulation

Anti-apoptosis

Angiogenesis: VEGF (neovascularization)

SCF (other progenitor cells)

Growth and differentiation factors

Antifibrotic Biomolecules

Biomolecules with chemotactic activity



Article

Clinical-Scale Mesenchymal Stem Cell-Derived Extracellular Vesicle Therapy for Wound Healing

Jieun Kim ^{1,2}, Eun Hee Kim ³, Hanbee Lee ^{1,2}, Ji Hee Sung ³ and Oh Young Bang ^{1,2,3,4,*}

¹ Cell and Gene Institute, Samsung Medical Center, Seoul 06351, Republic of Korea

² Translational and Stem Cell Research Laboratory on Stroke, Samsung Medical Center, Seoul 06351, Republic of Korea

³ S&E Bio, Inc., Seoul 05855, Republic of Korea

⁴ Department of Neurology, Samsung Medical Center, Sungkyunkwan University School of Medicine, Seoul 06351, Republic of Korea

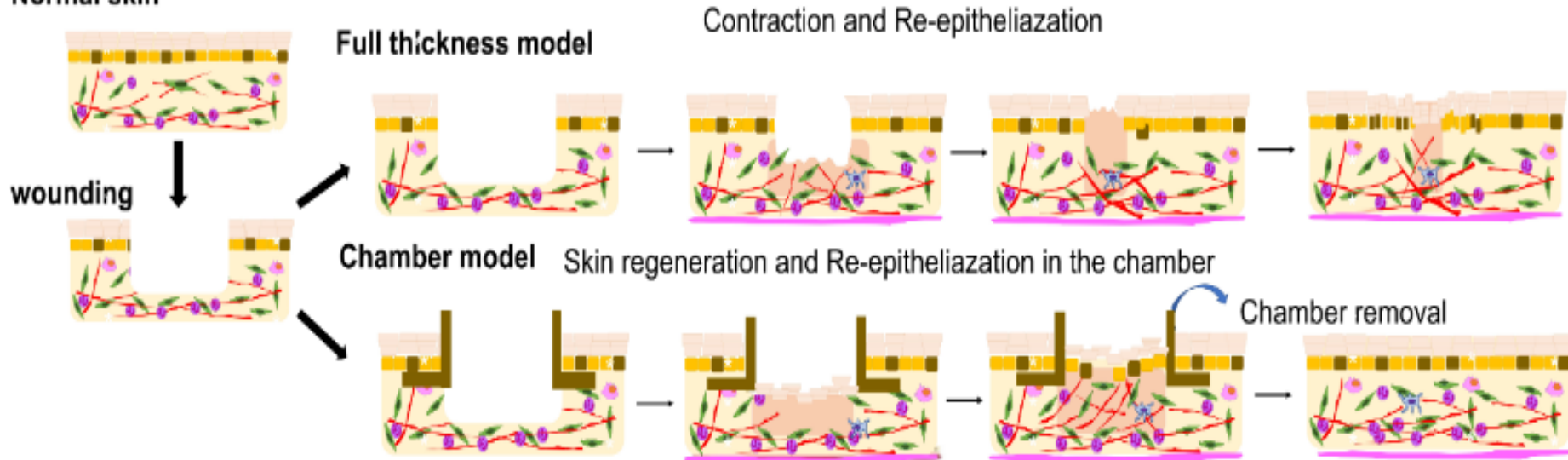
* Correspondence: ohyoung.bang@samsung.com

Abstract: We developed an extracellular vesicle (EV) bioprocessing platform for the scalable production of human Wharton's jelly mesenchymal stem cell (MSC)-derived EVs. The effects of clinical-scale MSC-EV products on wound healing were tested in two different wound models: subcutaneous injection of EVs in a conventional full-thickness rat model and topical application of EVs using a sterile re-absorbable gelatin sponge in the chamber mouse model that was developed to prevent the contraction of wound areas. In vivo efficacy tests showed that treatment with MSC-EVs improved the recovery following wound injury, regardless of the type of wound model or mode of treatment. In vitro mechanistic studies using multiple cell lines involved in wound healing showed that EV therapy contributed to all stages of wound healing, such as anti-inflammation and proliferation/migration of keratinocytes, fibroblasts, and endothelial cells, to enhance wound re-epithelialization, extracellular matrix remodeling, and angiogenesis.

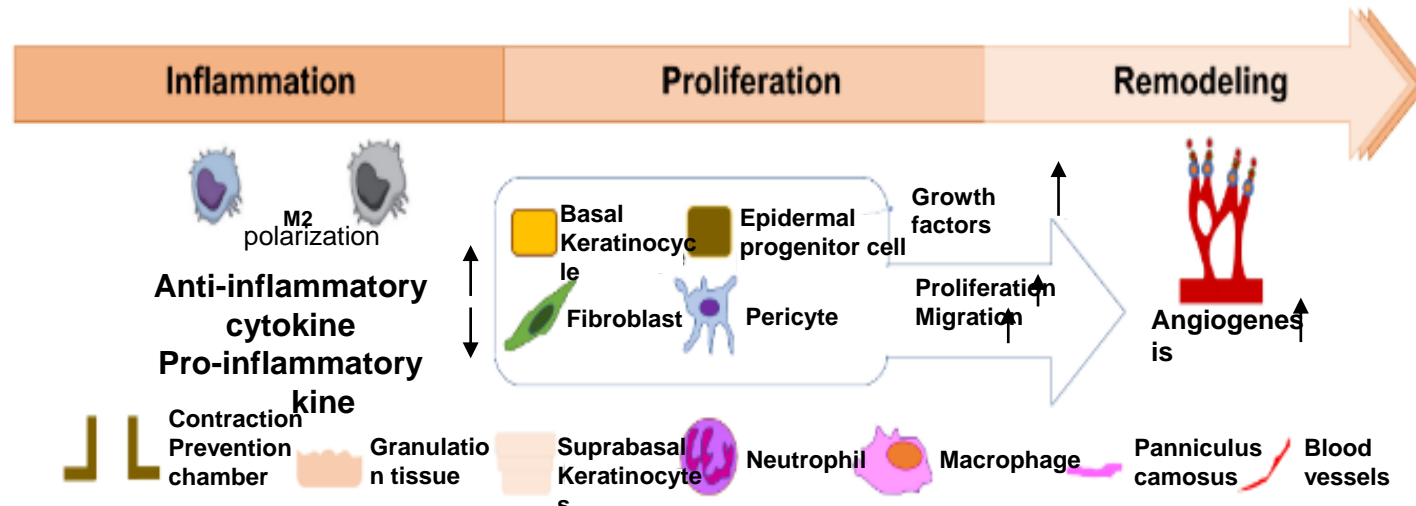
Keywords: mesenchymal stem cells; extracellular vesicles; exosomes; wound healing; functional recovery

In vivo POC using traditional full thickness and chamber wound models

Normal skin



Stages of wound healing

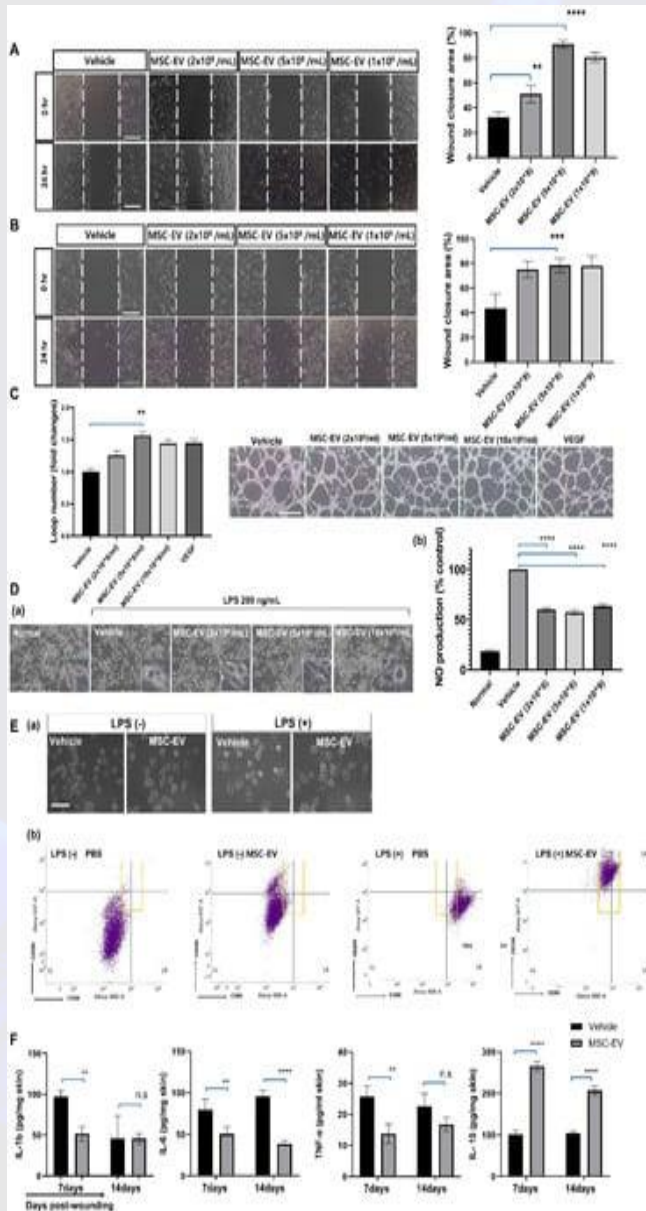


In vitro mechanism study of EV Therapy

GC x MSC-EVS
 Keratinocytes - HaCat
 Fibroblasts - NIH-3T3
 Endothelial Cells -
 HUVECs Inflammatory
 Cells - RAW264.7

↑CD206
 ↓CD80

M2>M1



Autologous composite graft for the treatment of complex/refractory ulcers

CHARACTERISTICS OF M-FAT

Minimal mechanical forces

Wash to remove oil and blood residues

Avoid the use of enzymes, additives, and centrifugation

Preservation of microarchitecture (vascular stromal niche)

Clusters of adipose tissue in intact agglomerates (250-650 microns)

Autologous composite graft for the treatment of complex/refractory ulcers

HYPODERMIS

15mm below the skin
Aspiration of hypodermic fat
Fragmentation of fat into microparticles without processing
Grafting into the wound bed

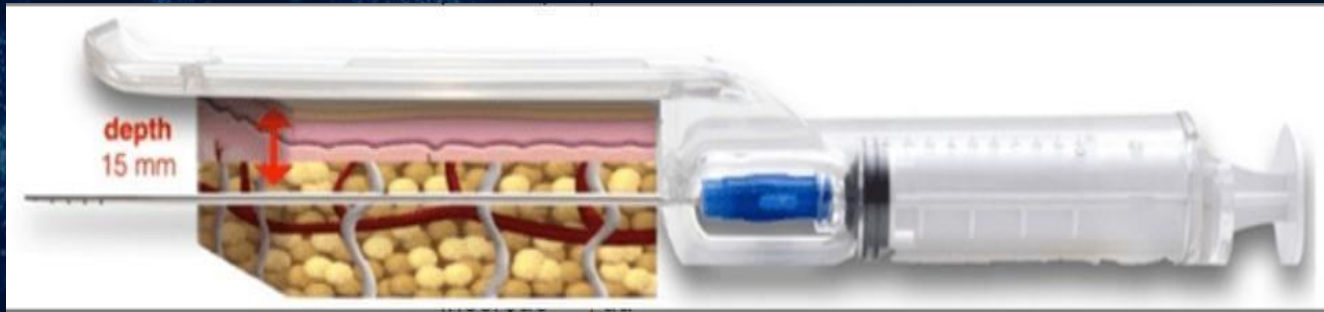
M-FAT HISTOLOGY

Adipocytes
Blood cells Vascular
Stromal Fraction - SVF:
ASC (Adipose-derived Stem Cells)

PERICYTES

ENDOTHELIAL PROGENITOR CELLS

Autologous composite graft for the treatment of complex/refractory ulcers



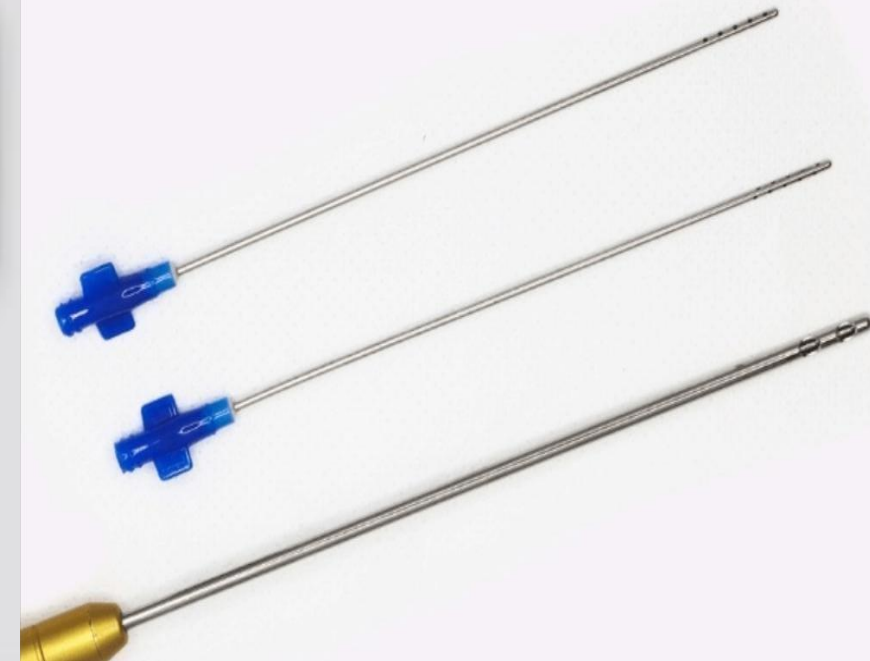
Qualitative and quantitative differences of adipose-derived stromal cells from superficial and deep subcutaneous lipoaspirates: a matter of fat

GIUSEPPE DI TARANTO^{1,2,7}, CLAUDIA CICIONE^{1,7}, GIUSEPPE VISCONTI², MARIA A. ISGRÒ³, MARTA BARBA³, ENRICO DI STASIO³, EGIDIO STIGLIANO⁴, CAMILLA BERNARDINI¹, FABRIZIO MICHETTI^{1,5}, MARZIA SALGARELLO^{2,1} & WANDA LATTANZI^{1,5,1}

Aesthet Surg J. 2014 May 1;34(4):601-13. doi: 10.1177/1090820X14528000. Epub 2014 Mar 31.

Harvest of superficial layers of fat with a microcannula and isolation of adipose tissue-derived stromal and vascular cells.

Trivisonno A¹, Di Rocco G, Cannistra C, Finocchi V, Torres Farr S, Monti M, Toietta G.



Stromal vascular fraction promotes migration of fibroblasts and angiogenesis through regulation of extracellular matrix in the skin wound healing process

Hongsen Bi ¹, Hui Li ², Chen Zhang ³, Yiqing Mao ², Fangfei Nie ³, Ying Xing ², Wuga Sha ², Xi Wang ², David M Irwin ⁴, Huanran Tan ⁵

Affiliations [+](#) expand

PMID: 31623669 PMCID: [PMC6798485](#) DOI: [10.1186/s13287-019-1415-6](#)

[Free PMC article](#)

Abstract

Background: A refractory wound is a typical complication of diabetes and is a common outcome after surgery. Current approaches have difficulty in improving wound healing. Recently, non-expanded stromal vascular fraction (SVF), which is derived from mature fat, has opened up new directions for the treatment of refractory wound healing. The aim of the current study is to systematically investigate the impact of SVF on wound healing, including the rate and characteristics of wound healing, ability of fibroblasts to migrate, and blood transport reconstruction, with a special emphasis on their precise molecular mechanisms.

The use of fat grafting and platelet-rich plasma for wound healing: A review of the current evidence

Oliver J Smith^{1 2}, Gavin Jell², Ash Mosahebi^{1 2}

Affiliations + expand

PMID: 30460739 PMCID: PMC7948810 DOI: 10.1111/iwj.13029

[Free PMC article](#)

Abstract

Fat grafting is becoming a common procedure in regenerative medicine because of its high content of growth factors and adipose derived stem cells (ADSCs) and the ease of harvest, safety, and low cost. The high concentration of ADSCs found in fat has the potential to differentiate into a wide range of wound-healing cells including fibroblasts and keratinocytes as well as demonstrating proangiogenic qualities. This suggests that fat could play an important role in wound healing. However retention rates of fat grafts are highly variable due in part to inconsistent vascularisation of the transplanted fat. Furthermore, conditions such as diabetes, which have a high prevalence of chronic wounds, reduce the potency and regenerative potential of ADSCs. Platelet-rich plasma (PRP) is an autologous blood product rich in growth factors, cell adhesion molecules, and cytokines. It has been hypothesised that PRP may have a positive effect on the survival and retention of fat grafts because of improved proliferation and differentiations of ADSCs, reduced inflammation, and improved vascularisation. There is also increasing interest in a possible synergistic effect that PRP may have on the healing potential of fat, although the evidence for this is very limited. In this review, we evaluate the evidence in both in vitro and animal studies on the mechanistic relationship between fat and PRP and how this translates to a benefit in wound healing. We also discuss future directions for both research and clinical practice on how to enhance the regenerative potential of the combination of PRP and fat.

Smith OJ, Jell G, Mosahebi A. The use of fat grafting and platelet-rich plasma for wound healing: A review of the current evidence. *Int Wound J.* 2019 Feb;16(1):275-285. doi: 10.1111/iwj.13029. Epub 2018 Nov 20. PMID: 30460739; PMCID: PMC7948810.

Review > Facial Plast Surg Clin North Am. 2018 Nov;26(4):487-501. doi: 10.1016/j.fsc.2018.06.009.

Epub 2018 Aug 16.

Mesothelial Stem Cells and Stromal Vascular Fraction: Use in Functional Disorders, Wound Healing, Fat Transfer, and Other Conditions

Greg Chernoff¹, Nathan Bryan², Andrea M Park³

Affiliations + expand

PMID: 30213429 DOI: 10.1016/j.fsc.2018.06.009

Abstract

Autologous human fat-derived mesenchymal stem cells are present in stromal vascular fraction. Stromal vascular fraction can be easily and safely extracted from lipoaspirate. The regenerative, antiinflammatory and immunomodulatory effects of stromal vascular fraction are being documented in ongoing therapeutic response studies.

Chernoff G, Bryan N, Park AM. Mesothelial Stem Cells and Stromal Vascular Fraction: Use in Functional Disorders, Wound Healing, Fat Transfer, and Other Conditions. Facial Plast Surg Clin North Am. 2018 Nov;26(4):487-501. doi: 10.1016/j.fsc.2018.06.009. Epub 2018 Aug 16. PMID: 30213429.

Epub 2020 Jul 7.

Fat grafting and platelet-rich plasma for the treatment of diabetic foot ulcers: A feasibility-randomised controlled trial

Oliver J Smith ^{1 2}, Richard Leigh ³, Muholan Kanapathy ¹, Peter Macneal ⁴, Gavin Jell ², Nadine Hachach-Haram ¹, Haroon Mann ⁵, Ash Mosahebi ^{1 2}

Affiliations + expand

PMID: 32633854 PMCID: PMC7949265 DOI: 10.1111/iwj.13433

[Free PMC article](#)

Abstract

Chronic, nonhealing diabetic foot ulcers (DFU) are increasing in prevalence and are often unresponsive to conventional therapy. Adipose tissue, containing adipose-derived stem cells, and platelet rich plasma (PRP) are regenerative therapies rich in growth factors which may provide a solution to chronic wound healing. This study aimed to assess the feasibility of conducting a definitive randomised controlled trial (RCT) to investigate the efficacy of these therapies for the treatment of DFU. This was a single centre, feasibility, three-arm, parallel group RCT. Eligible DFU patients were randomised on a 1:1:1 basis to three intervention arms: control (podiatry); fat grafting; fat grafting with PRP. The intervention was delivered once and patients were followed-up for 12 weeks. The primary objective was to assess measures of trial feasibility. Clinical outcomes and health-related quality of life (HRQoL) were also evaluated. Three hundred and thirty four patients were screened and 32 patients (9.6%) were deemed eligible with 18 enrolled in the trial (6 per arm) over 17 months. All participants completed the trial with no withdrawals or crossover. Participant engagement was high with most HRQoL questionnaires returned and only 4.8% follow-up appointments missed. There were five adverse events (AEs) related to the trial with no serious AEs. Five (28%) of the wounds healed. There was no difference between any of the groups in terms of clinical outcomes. This feasibility study demonstrated that a multi-centre RCT is safe and feasible with excellent patient engagement. We have highlighted crucial information regarding methodology and recruitment, which will guide future trial design. Registration number: [NCT03085550](#) clinicaltrials.gov. Registered 01/03/2017.

Smith OJ, Leigh R, Kanapathy M, Macneal P, Jell G, Hachach-Haram N, Mann H, Mosahebi A. Fat grafting and platelet-rich plasma for the treatment of diabetic foot ulcers: A feasibility-randomised controlled trial. Int Wound J. 2020 Dec;17(6):1578-1594. doi: 10.1111/iwj.13433. Epub 2020 Jul 7. PMID: 32633854; PMCID: PMC7949265.

Regional Implantation of Autologous Adipose Tissue-Derived Cells Induces a Prompt Healing of Long-Lasting Indolent Digital Ulcers in Patients With Systemic Sclerosis

Nicoletta Del Papa,* Gabriele Di Luca,† Domenico Sambataro,* Eleonora Zaccara,* Wanda Maglione, Armando Gabrielli,‡ Paolo Fraticelli,‡ Gianluca Moroncini,‡ Lorenzo Beretta,§ Alessandro Santaniello, Gianluca Sambataro,¶ Roberto Ferraresi,# and Claudio Vitali**

*U.O.C. Day Hospital Reumatologia, Ospedale G. Pini, Milano, Italy

†U.O.S. Chirurgia Vascolare, Ospedale G. Pini, Milano, Italy

‡U.O. Clinica Medica, Dipartimento di Medicina Interna, Ospedali Riuniti, Ancona, Italy

§Centro di Riferimento per le Malattie Autoimmuni Sistemiche, Fondazione IRCCS Ca' Granda Ospedale Maggiore Policlinico di Milano, Milano, Italy

¶Dipartimento Medicina Interna e Reumatologia, Campus Biomedico, Roma, Italy

#Laboratorio Emodinamica Periferica Interventistica, Humanitas Gavazzeni, Bergamo, Italy

**Servizio di Reumatologia, Istituto San Giuseppe, Anzano del Parco, Como, Italy

Table 1. Clinical Characteristics and Outcome of Patients Treated With Autologous Adipose Tissue

Case	Age/ Gender	Diagnosis	Ischemic Site	DU Max. Diameter (mm)	DU Duration (Weeks)	DU Healing (Weeks)
1	53/F	lcSSc	Left, 3° finger	5.8	28	2.5
2	56/F	dcSSc	Right, 4° finger	9.1	20	5
3	64/F	dcSSc	Right, 2° finger	10	20	6
4	63/F	dcSSc	Right, 3° finger	7.3	32	7
5	49/F	dcSSc	Left, 3° finger	8	36	6
6	59/F	dcSSc	Left, 4° finger	6.4	38	3
7	47/F	lcSSc	Left, 2° finger	6	25	5
8	43/F	lcSSc	Right, 3° finger	7	24	5
9	66/F	dcSSc	Right, 4° finger	8.5	20	4
10	58/F	lcSSc	Left, 3° finger	6.2	24	5
11	50/F	dcSSc	Left, 4° finger	6.8	24	4
12	52/F	dcSSc	Right, 2° finger	8	34	3
13	36/F	lcSSc	Left, 2° finger	7.2	20	3
14	43/F	lcSSc	Right, 5° finger	6.4	24	3
15	40/F	dcSSc	Right, 2° finger	5.5	22	2

For abbrev

Digital ulcers (DUs) are a rather frequent and invalidating complication in systemic sclerosis (SSc), often showing a very slow or null tendency to heal, in spite of the commonly used systemic and local therapeutic procedures. Recently, stem cell therapy has emerged as a new approach to accelerate wound healing. In the present study, we have tentatively treated long-lasting and poorly responsive to traditional therapy SSc-related DUs by implantation of autologous adipose tissue-derived cell (ATDC) fractions. Fifteen patients with SSc having a long-lasting DU in only one fingertip who were unresponsive to intensive systemic and local treatment were enrolled in the study. The grafting procedure consisted of the injection, at the basis of the corresponding finger, of 0.5–1 ml of autologous ATDC fractions, separated by centrifugation of adipose tissue collected through liposuction from subcutaneous abdominal fat. Time to heal after the procedure was the primary end point of the study, while reduction of pain intensity and of analgesic consumption represented a secondary end point. Furthermore, the posttherapy variation of the number of capillaries, observed in the nailfold video capillaroscopy (NVC) exam and of the resistivity in the digit arteries, measured by high-resolution echolor-Doppler, were also taken into account. A rather fast healing of the DUs was reached in all of the enrolled patients (mean time to healing 4.23 weeks; range 2–7 weeks). A significant reduction of pain intensity was observed after a few weeks ($p < 0.001$), while the number of capillaries was significantly increased at 3- and 6-month NVC assessment ($p < 0.0001$ in both cases). Finally, a significant after-treatment reduction of digit artery resistivity was also recorded ($p < 0.0001$). Even with the limitations related to the small number of patients included and to the open-label design of the study, the observed strongly favorable outcome suggests that local grafting with ATDCs could represent a promising option for the treatment of SSc-related DUs unresponsive to more consolidated therapies.

Key words: Systemic sclerosis; Adipose tissue; Stem cells; Autologous graft; Ulcers

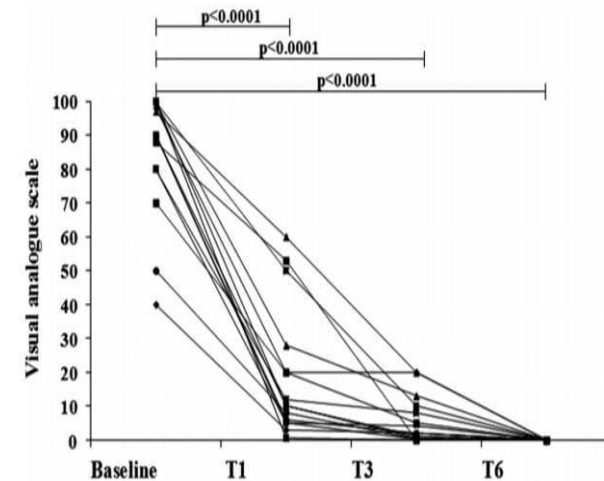


Figure 2. Changes in pain severity after autologous ATDC treatment. Changes in pain severity assessed by visual analogue scale (VAS, ranging from 0 to 100) after autologous ATDCs treatment. All of the treated patients experienced a significant improvement during the weeks of observation.

Regional Implantation of Autologous Adipose Tissue-Derived Cells Induces a Prompt Healing of Long-Lasting Indolent Digital Ulcers in Patients With Systemic Sclerosis

Nicoletta Del Papa,* Gabriele Di Luca,† Domenico Sambataro,* Eleonora Zaccara,* Wanda Maglione,* Armando Gabrielli,‡ Paolo Fraticelli,‡ Gianluca Moroncini,‡ Lorenzo Beretta,§ Alessandro Santaniello,§ Gianluca Sambataro,¶ Roberto Ferraresi,# and Claudio Vitali**

*U.O.C. Day Hospital Reumatologia, Ospedale G. Pini, Milano, Italy

†U.O.S. Chirurgia Vascolare, Ospedale G. Pini, Milano, Italy

‡U.O. Clinica Medica, Dipartimento di Medicina Interna, Ospedali Riuniti, Ancona, Italy

§Centro di Riferimento per le Malattie Autoimmuni Sistemiche, Fondazione IRCCS Ca' Granda Ospedale Maggiore Policlinico di Milano, Milano, Italy

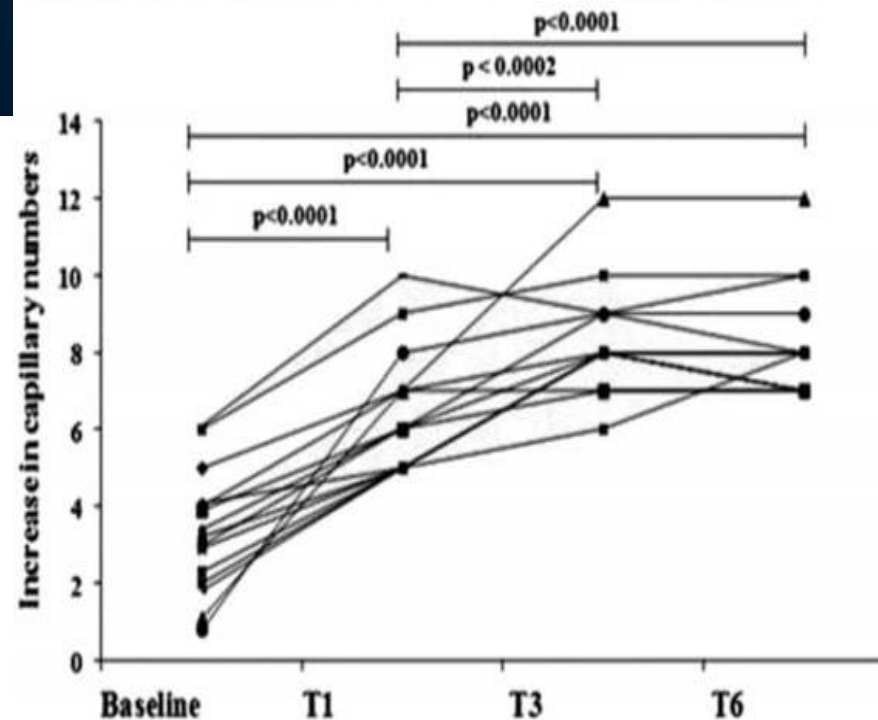
¶Dipartimento Medicina Interna e Reumatologia, Campus Biomedico, Roma, Italy

#Laboratorio Emodinamica Periferica Interventistica, Humanitas Gavazzeni, Bergamo, Italy

**Servizio di Reumatologia, Istituto San Giuseppe, Anzano del Parco, Como, Italy

Digital ulcers (DUs) are a rather frequent and invalidating complication in systemic sclerosis (SSc), often showing a very slow or null tendency to heal, in spite of the commonly used systemic and local therapeutic procedures. Recently, stem cell therapy has emerged as a new approach to accelerate wound healing. In the present study, we have tentatively treated long-lasting and poorly responsive to traditional therapy SSc-related DUs by implantation of autologous adipose tissue-derived cell (ATDC) fractions. Fifteen patients with SSc having a long-lasting DU in only one fingertip who were unresponsive to intensive systemic and local treatment were enrolled in the study. The grafting procedure consisted of the injection, at the basis of the corresponding finger, of 0.5–1 ml of autologous ATDC fractions, separated by centrifugation of adipose tissue collected through liposuction from subcutaneous abdominal fat. Time to heal after the procedure was the primary end point of the study, while reduction of pain intensity and of analgesic consumption represented a secondary end point. Furthermore, the posttherapy variation of the number of capillaries, observed in the nailfold video capillaroscopy (NVC) exam and of the resistivity in the digit arteries, measured by high-resolution echocolor-Doppler, were also taken into account. A rather fast healing of the DUs was reached in all of the enrolled patients (mean time to healing 4.23 weeks; range 2–7 weeks). A significant reduction of pain intensity was observed after a few weeks ($p < 0.001$), while the number of capillaries was significantly increased at 3- and 6-month NVC assessment ($p < 0.0001$ in both cases). Finally, a significant after-treatment reduction of digit artery resistivity was also recorded ($p < 0.0001$). Even with the limitations related to the small number of patients included and to the open-label design of the study, the observed strongly favorable outcome suggests that local grafting with ATDCs could represent a promising option for the treatment of SSc-related DUs unresponsive to more consolidated therapies.

Key words: Systemic sclerosis; Adipose tissue; Stem cells; Autologous graft; Ulcers



AUTOLOGOUS FAT GRAFT IN SYSTEMIC SCLEROSIS ULCERS

230

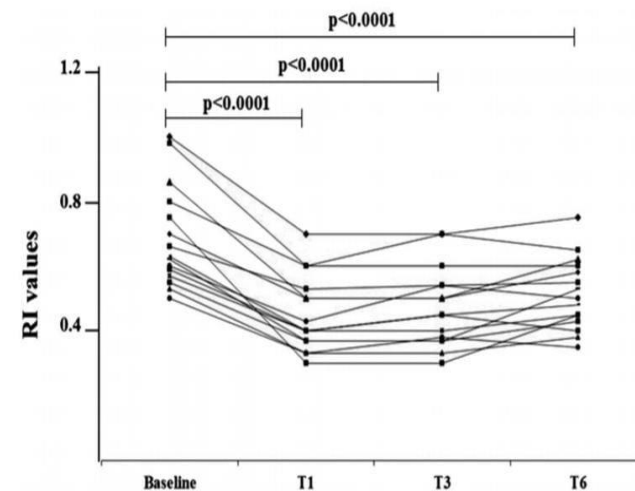


Figure 4. Changes in local vascularization after autologous ATDC treatment. The high-resolution echocolor-Doppler examination of the treated digit artery of the patients showed a significant reduction of RI values at T1, T3, and T6 in comparison with T0. No significant differences were noticed between values recorded at T1 with respect to T3 and T6 and at T3 with respect to T6.

RECONSTRUCTIVE

Débridement and Autologous Lipotransfer for Chronic Ulceration of the Diabetic Foot and Lower Limb Improves Wound Healing

Tilman Stasch, M.B.Ch.B.,
M.D.
Julius Hoehne, M.D.
Tuan Huynh
Randy De Baerdemacker,
M.D.
Siegfried Grandel, M.D.
Christian Herold, M.D.,
Ph.D.
Cologne, Aachen, and Hameln,
Germany

Background: The application of autologous lipotransfer (fat grafting, lipofilling) in reconstructive surgery is steadily becoming more popular as evidence of the regenerative and reparative effects of fat becomes better known. The authors investigated the use of autologous lipotransfer for treatment of chronic diabetic and other foot and lower limb ulcers.

Methods: Twenty-six patients with nonhealing wounds were treated with surgical débridement and autologous lipotransfer (using the débridement and autologous lipotransfer method). The mean age of the wounds before intervention was 16.7 months. Wound size after débridement averaged $5.1 \pm 2.6 \text{ cm}^2$.

On average, $7.1 \pm 3.3 \text{ cc}$ of lipoaspirate was transferred into the wound area. **Results:** Twenty-two of 25 wounds (88 percent) healed completely within a mean of 68.0 ± 33.0 days. A reduction of wound size by 50 percent was achieved after an average of 4 weeks. In one patient with an ulcer within particularly scarred tissues on the lower limb, a repeated session of lipotransfer led to complete wound healing after another 4 weeks.

Conclusion: The authors describe a simple and useful technique to improve wound healing in diabetic feet and chronic lower limb ulcers with a background of peripheral vascular disease, where other interventional options to achieve wound healing have failed. (*Plast. Reconstr. Surg.* 136: 1357, 2015.)

CLINICAL QUESTION/LEVEL OF EVIDENCE: Therapeutic, IV.





Table 1. Patient Profiles and Wound Characteristics

Patient	Age (yr)	Sex	Diabetic	PVD	CRF	Wound Type	Location	Ulcer Age (mo)	Fat Used (ml)	Wound Size (cm^2)	Healed (days)
1	57	M	No	Yes	No	Chronic wound after trauma	Pretibial	9	4	1.7	95
2	67	M	No	Yes	No	Pressure sore	Plantar	1	11	5.3	80
3	25	M	No	No	No	Chronic wound after trauma	Pretibial	5	2	1.9	60
4	55	M	Yes	Yes	No	Pressure sore	Plantar	19	8	5.4	60
5	50	M	Yes	No	No	Pressure sore	Plantar	12	6	2.3	40
6	76	M	No	No	No	Chronic wound after elective surgery	Dorsal foot	2	2	2.0	50
7	40	F	No	No	No	Pressure sore	Plantar	18	5	2.0	48
8	74	M	Yes	No	Yes	Pressure sore	Plantar	3	10	8.4	70
9	46	F	No	No	No	Pressure sore	Plantar	4	15	5.5	95
10	56	F	No	No	No	Pressure sore	Plantar	72	7	3.2	+
11	51	F	Yes	No	No	Pressure sore	Plantar	9	2.5	5.4	++
12	45	F	No	No	No	Chronic wound after elective surgery	Dorsal foot	3	6	6.3	100
13	62	M	No	Yes	No	Chronic scars after fracture	Distal lower limb	6	8	3.1	40
14	52	F	Yes	Yes	No	Chronic scars after fracture	Distal lower limb	8	6	3.4	107*
15	42	F	Yes	No	No	Chronic wound after trauma	Pretibial	3	6	6.8	80
16	62	M	Yes	Yes	No	Pressure sore	Plantar	8	6	5.1	80
17	85	F	No	Yes	Yes	Pressure sore	Heel	4	9	6.9	100
18	54	M	Yes	No	No	Chronic wound after trauma	Distal lower limb	24	8	3.8	63
19	66	M	Yes	Yes	No	Pressure sore	Heel	43	2	1.4	40
20	63	M	Yes	Yes	No	Chronic venous ulcer	Distal lower limb	12	9	10.0	+++
21	68	F	Yes	Yes	Yes	Pressure sore, Charcot	Plantar	5	5	8.0	+++
22	63	M	Yes	Yes	Yes	Pressure sore, Charcot	Plantar	18	10	9.8	107
23	76	M	Yes	Yes	Yes	Chronic venous ulcer	Distal lower limb	18	6	5.3	62
24	61	M	Yes	No	No	Chronic venous ulcer	Distal lower limb	52	10	7.4	42
25	61	M	Yes	No	No	Chronic venous ulcer	Distal lower limb	52	14	9.5	51
26	56	M	Yes	Yes	No	Pressure sore	Heel	24	6	2.8	65
Mean \pm SD	58.2 \pm 12.6							16.7 \pm 18.0	7.1 \pm 3.3	5.1 \pm 2.6	68.0 \pm 33.0

+, wound healed after 330 days; ++, patient moved away after 71 days; +++, skin grafting after 4 wk; +++, poor compliance, refused repeated lipotransfer.

*Second lipotransfer on day 50.

Human Macrophages Preferentially Infiltrate the Superficial Adipose Tissue

Giuseppe Cappellano¹, Evi M. Morandi¹ , Johannes Rainer² , P. Katharina Heinz³, Dolores Wolfram¹, David Bernhard⁴, Susanne I. and Christian Ploner^{1,*}

¹ Department of Plastic, Reconstructive and Aesthetic Surgery, Medical University of Innsbruck, Anichstrasse 35, 6020 Innsbruck, Austria; giuseppe.cappellano@i-med.ac.at (G.C.); evi.morandi@tirol-kliniken.at (E.M.M.); philipp.grubwieser@student.i-med.ac.at (P.K.H.); dolores.wolfram@i-med.ac.at (D.W.); susanne.lobenwein@i-med.ac.at (S.I.); gerhard.pierer@i-med.ac.at (G.P.)

² Institute for Biomedicine, Eurac Research, Affiliated Institute of the University of Bolzano, 39100 Bolzano, Italy; johannes.rainer@eurac.edu

³ Cardiac Surgery Research Laboratory, University Clinic for Cardiac Surgery, Medical University of Innsbruck, 6020 Innsbruck, Austria; katharina.heinz@i-med.ac.at

⁴ Center for Medical Research, Medical Faculty, Johannes-Kepler-University of Linz, 4020 Linz, Austria; david.bernhard@jku.at

* Correspondence: christian.ploner@i-med.ac.at; Tel.: +43-512-504-82648

Received: 20 April 2018; Accepted: 5 May 2018; Published: 8 May 2018

Abstract: Human abdominal subcutaneous adipose tissue consists of superficial adipose tissue (SAT) and deep adipose tissue (DAT)—see Figure 1. The present study focuses on the analysis of morphological and primary adipocytes, adipose-derived stem cells (ASC), and tissue-infiltrating immune cells found in SAT and DAT. Adipocytes and stromal vascular fraction (SVF) cells were isolated from human SAT and DAT specimens and phenotypically characterized by *in vitro* assays. *Ex vivo* analysis of infiltrating immune cells was performed by flow cytometry. Primary adipocytes from SAT are larger in size but did not significantly differ in cytokine levels of LEPTIN, ADIPOQ, RBP4, CHEMERIN, DEFB1, VSFATIN, MCP1, or MSCF. ASC isolated from SAT proliferated faster and exhibited a higher differentiation potential than those isolated from DAT. Flow cytometry analysis indicated no specific differences in the relative numbers of ASC, epithelial progenitor cells (EPC), or CD3⁺ T-cells, but showed higher numbers of tissue-infiltrating macrophages in SAT compared to DAT. Our findings suggest that ASC isolated from SAT have a higher regenerative potential than DAT-ASC. Moreover, spatial proximity to skin microbiota might promote macrophage infiltration in SAT.

Keywords: adipose-derived stem cells; superficial adipose tissue; deep adipose tissue; immune cell infiltration; macrophages

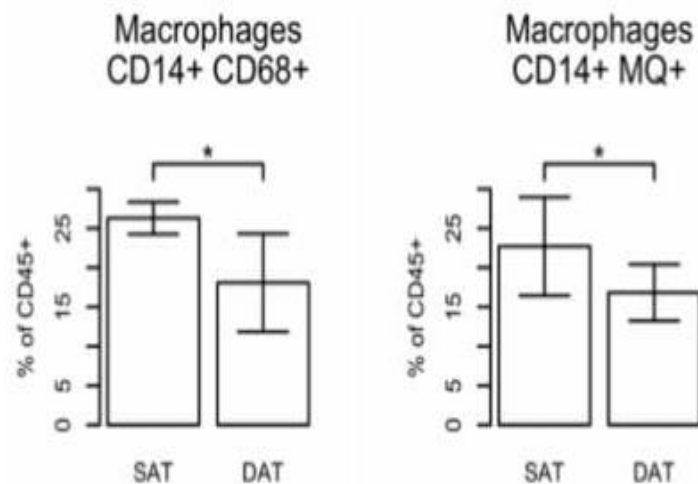
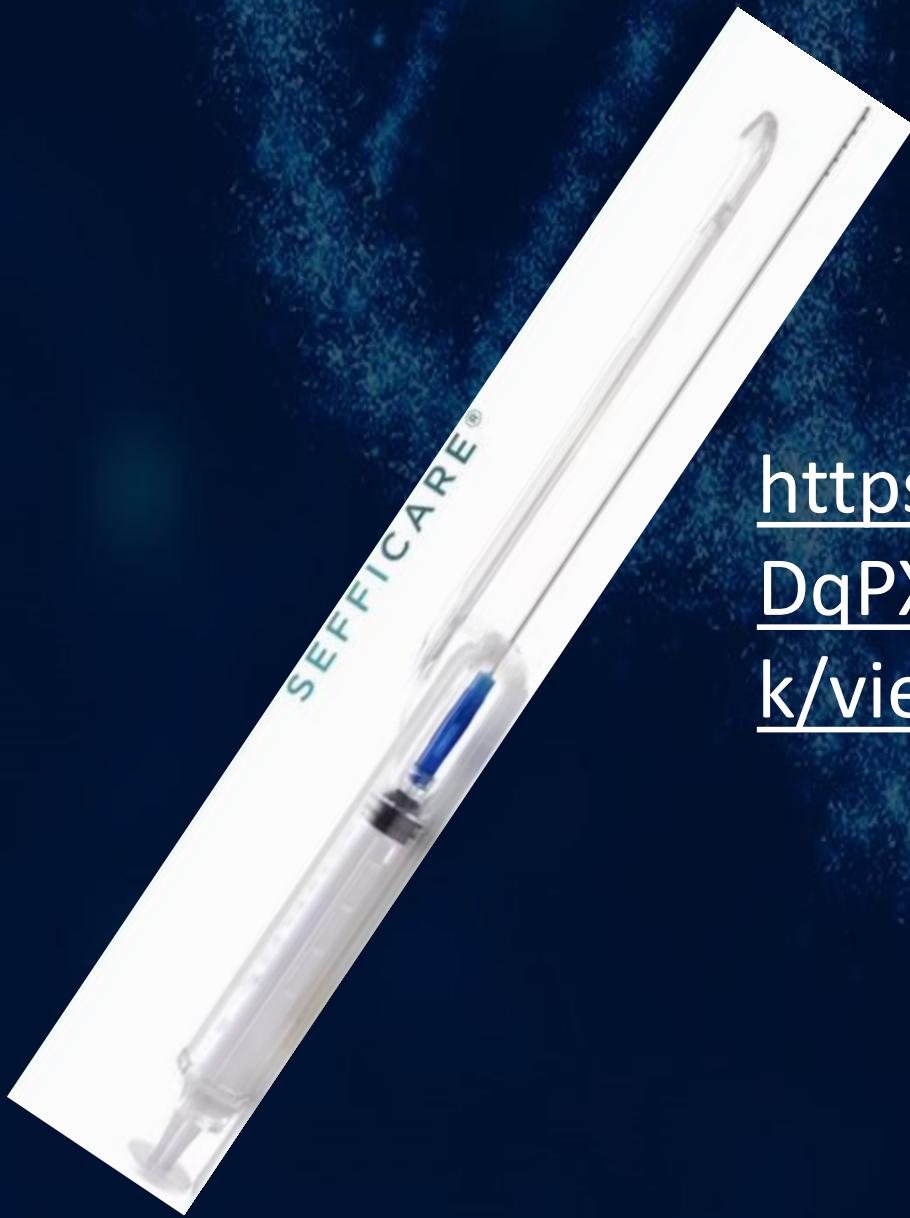


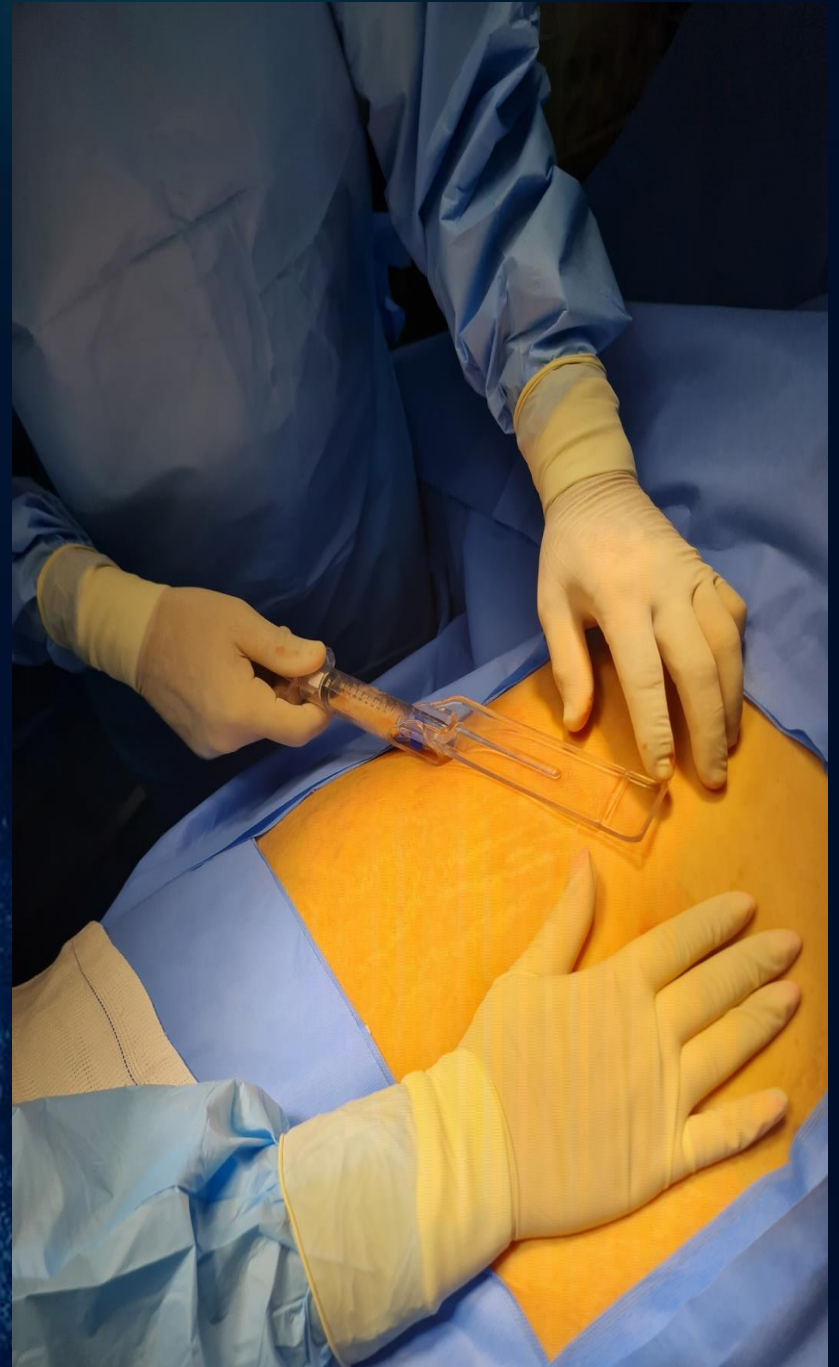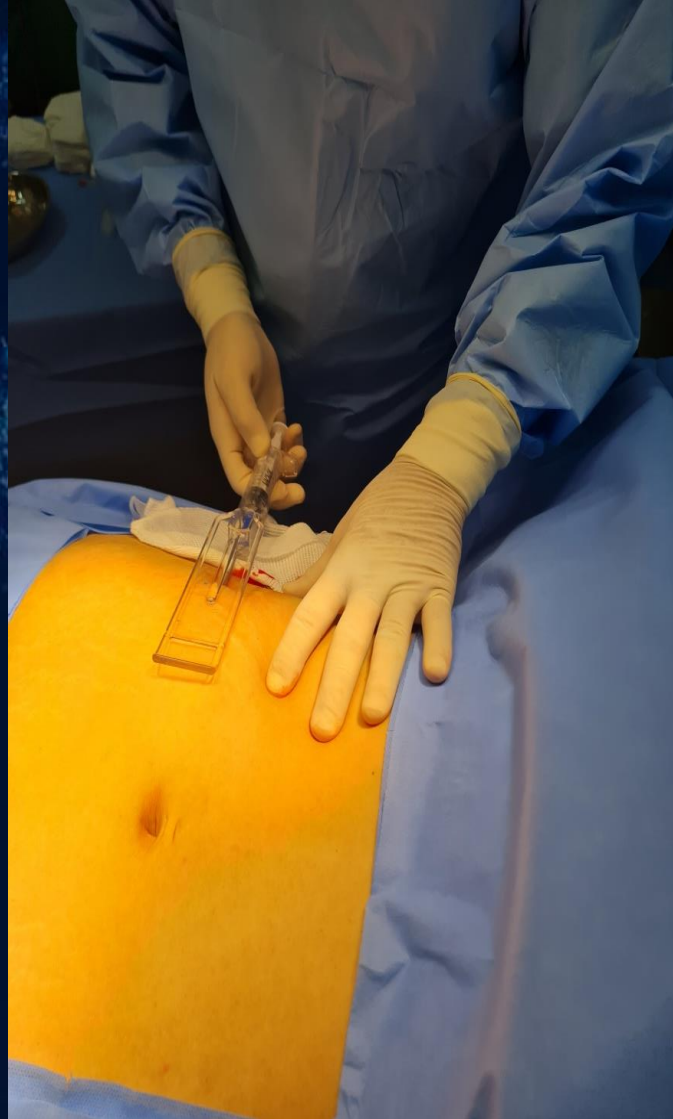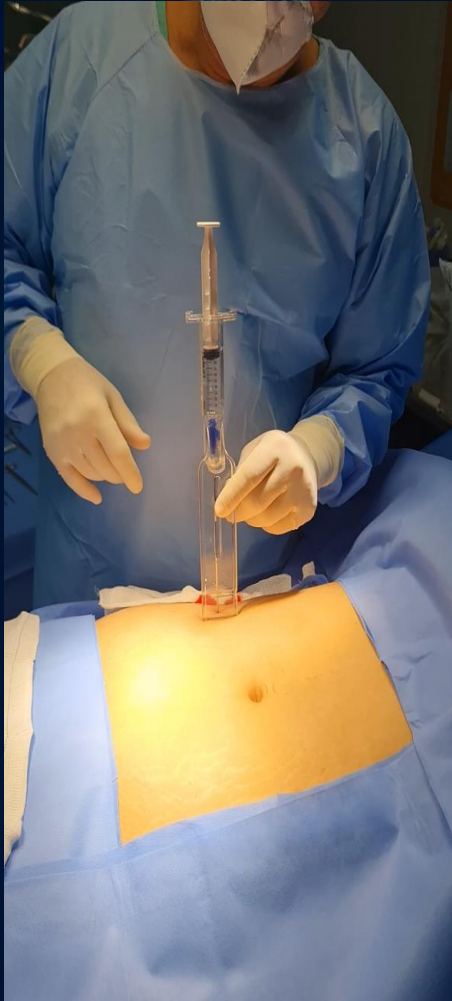Figure 6. Macrophage infiltration in SAT and DAT. Gating strategy is shown in Figure 4A. Macrophages (defined as CD14⁺CD68⁺ or CD14⁺ MΦ⁺ (clone 25f9)) are shown as % of CD45⁺ cells. Results represent data from four patients and are expressed as mean ± SD. Significance of the difference in means was calculated using a paired *t*-test (* *p*-value < 0.05).

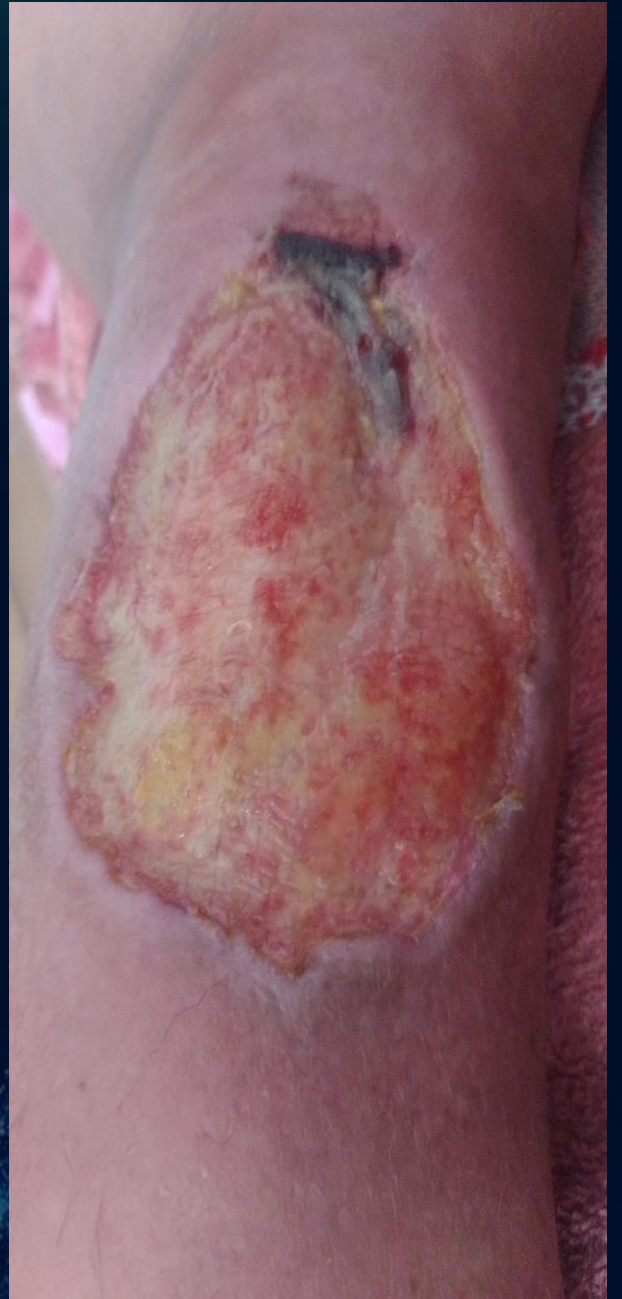
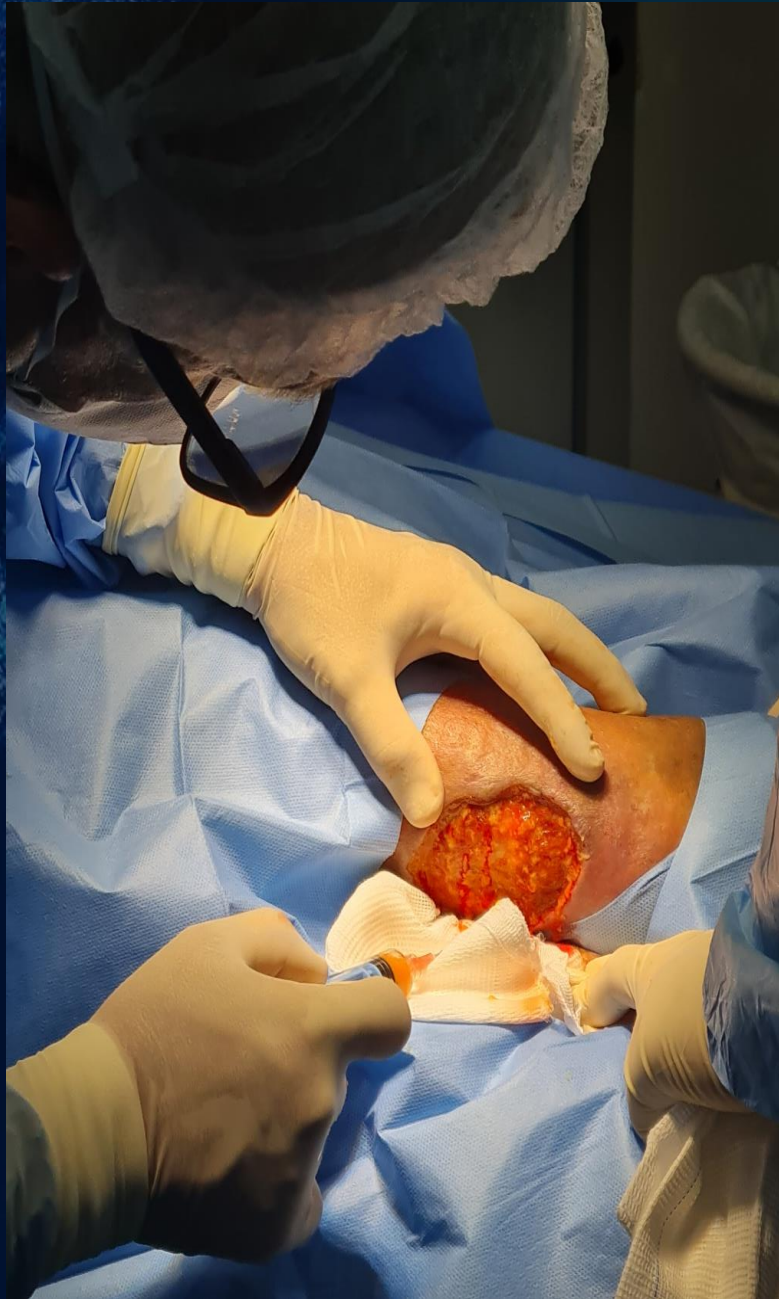
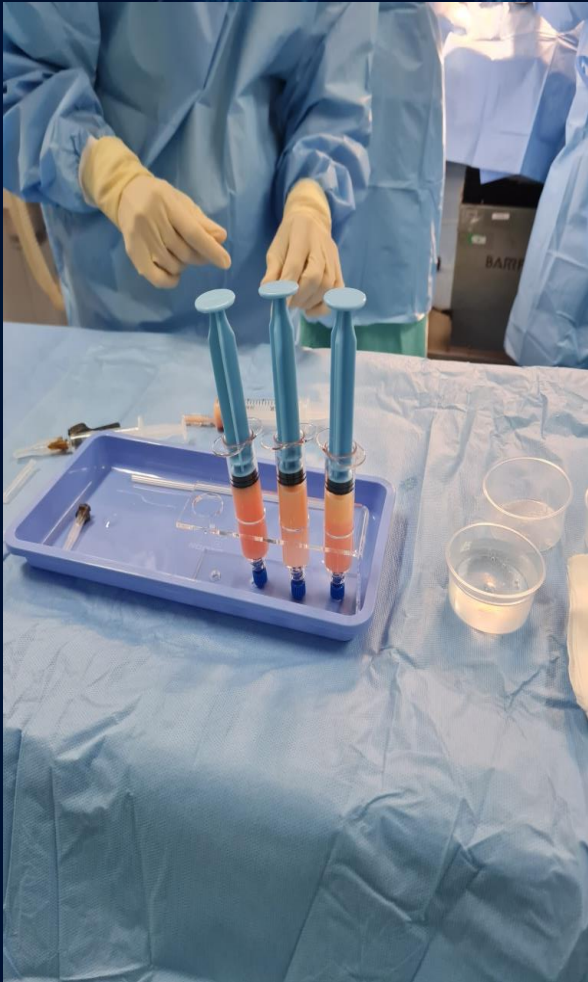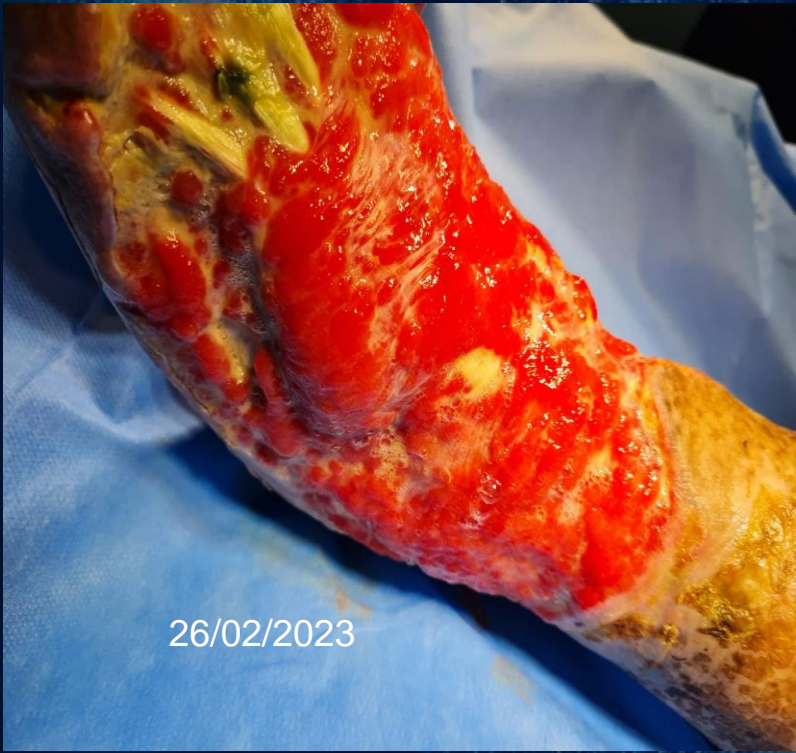Script and Technique



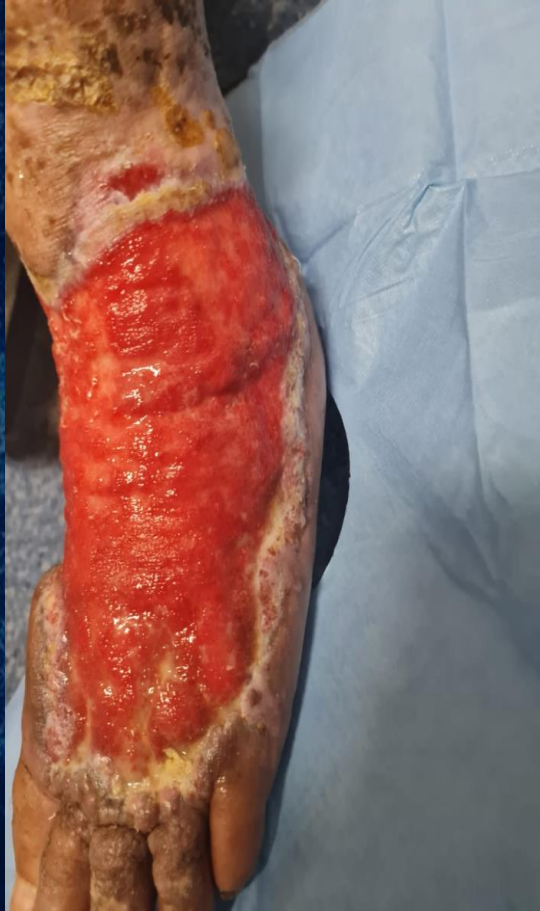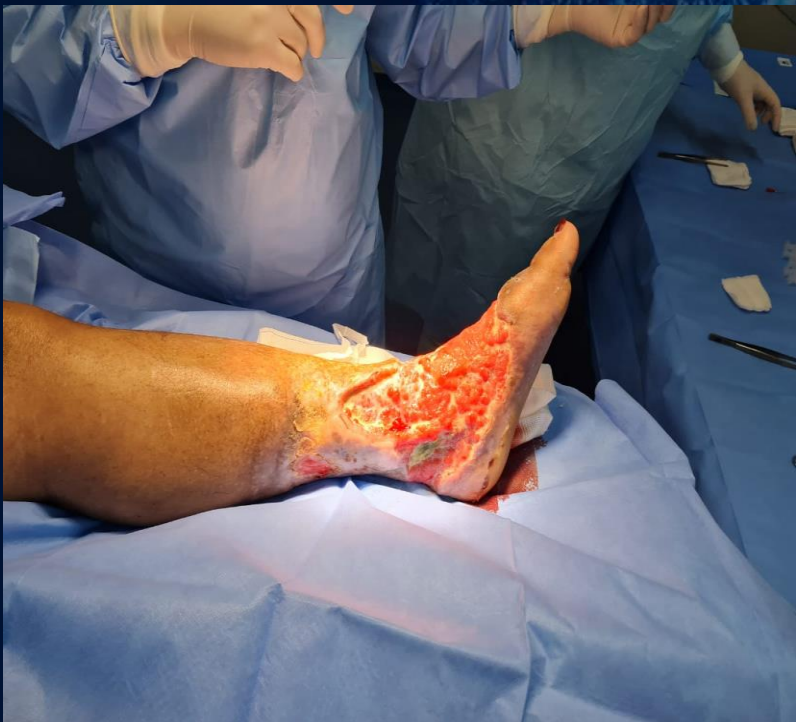<https://drive.google.com/file/d/1VyDqPXc4T0OW1zF-rnhr8o3fyPIQD1-k/view?usp=sharing>



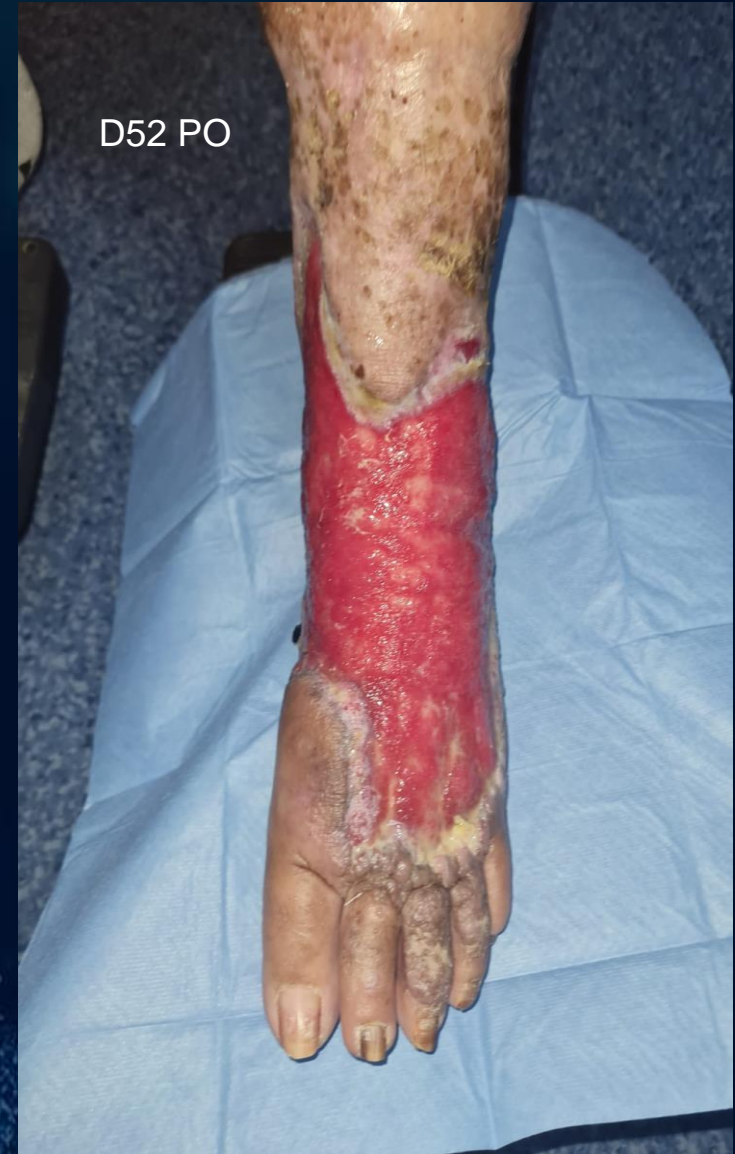



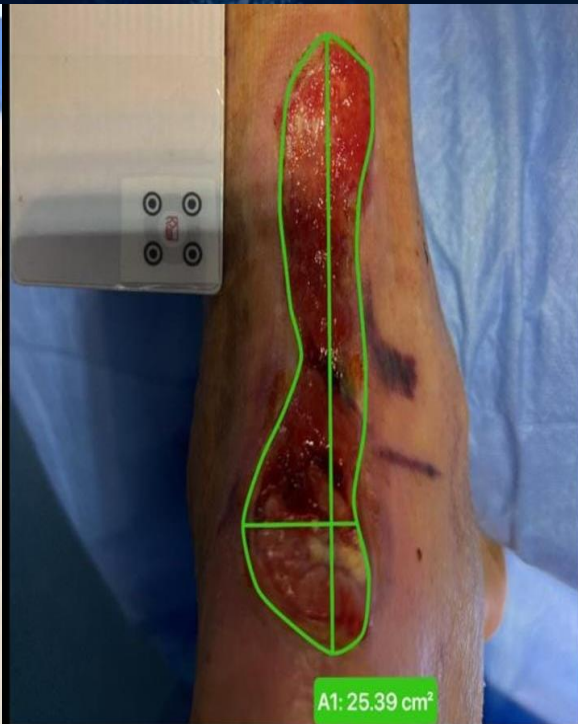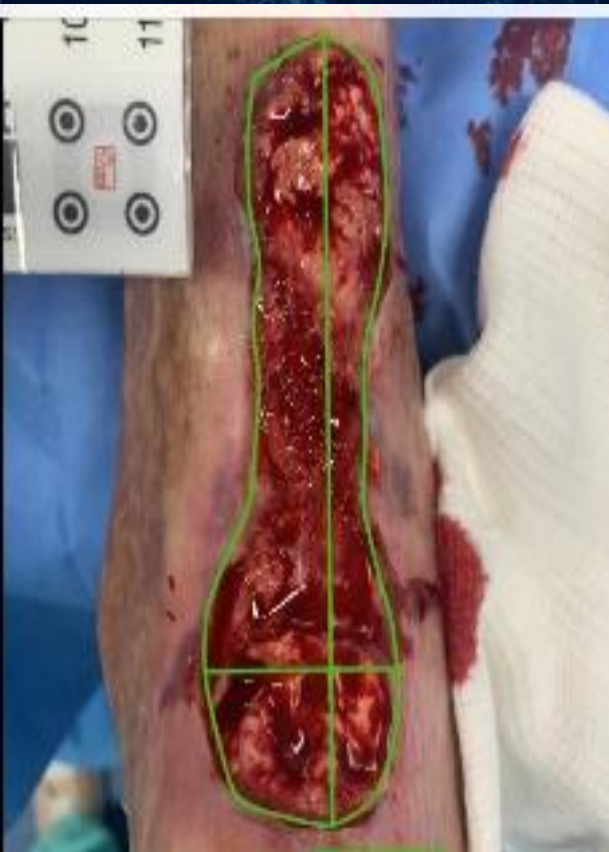26/02/2023



CASE 18



D52 PO



• A1

Área 25.39 cm²

Circunferência 27.84 cm

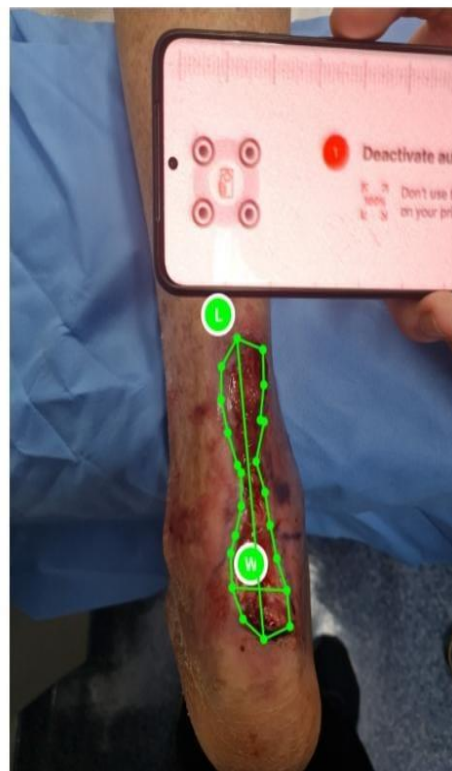
Comprimento 12.41 cm

Largura 2.91 cm

C1 JVB



Measurement Report



Data: PM-09-22 14: 38

Área: 3,81

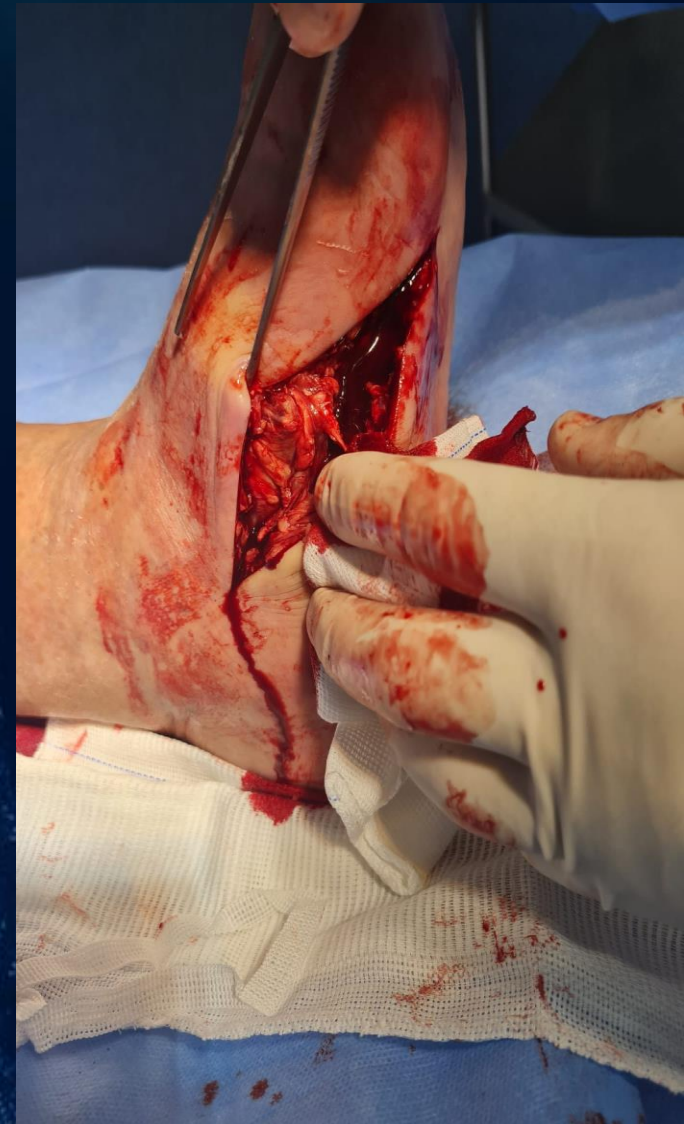Largura: 1,1

Comprimento: 5,1

Circunferência: 11,56

Comment:

Patient, 75 years old, Type 2 Diabetes Mellitus (DM2), infected diabetic neuropathy, WIFI 302, history of multiple fractures in the tarsal bones, osteomyelitis. Referred to the service with a severe infection in the midfoot associated with multiple fractures of the tarsal bones. Ascending erythema towards the ankle joint. Indication of amputation in the medical record.



STRATEGY: Imaging exams, sequential debridements with cultures and antibiograms after each surgical approach, Hyperbaric Oxygen Therapy, wound bed preparation, Microfragmented Fat Cellular Therapy, Hyperbaric Oxygen Therapy.

CT

Preparo do Solo

Redução difusa da densidade óssea.

Fratura no aspecto anterior do calcâneo, sem desalinhamento ósseo significativo, comprometendo a superfície articular.

Fratura cominutiva no cubóide, com comprometimento das superfícies articulares e desalinhamento dos fragmentos ósseos.

Fratura no aspecto anterossuperior do tálus.

Fratura cominutiva no navicular, com desalinhamento de fragmentos ósseos, que se apresentam destacados em partes moles adjacentes, o maior deles medialmente, medindo cerca de 2,1 cm.

Fratura cominutiva nos cuneiformes medial, intermédio e lateral, com sinais de impactação óssea do cuneiforme medial com o navicular.

Aparente fratura no aspecto medial da base do primeiro metatarso, sem desalinhamento ósseo significativo.

Fratura cominutiva nas bases dos segundo e terceiro metatarsos, comprometendo as superfícies articulares.

Diminuto cisto subcortical na base do quarto metatarso.

Redução dos espaços articulares tarsometatarsais.

Demais espaços articulares mantidos.

Não há sinais de derrame articular significativo.

Entesopatia calcificada incipiente na fásia plantar e na inserção do tendão calcâneo.

Calcificações ateromatosas parietais vasculares.

Leve infiltração difusa dos planos músculo-adiposos.

Não há sinais evidentes de reação periosteal ou coleções organizadas detectáveis ao método.

Nota: O presente método tem baixa sensibilidade na detecção de possíveis lesões tendíneas, ligamentares ou cartilaginosas, sendo a Ressonância Magnética o exame de escolha.

RESSONÂNCIA MAGNÉTICA DO PÉ ESQUERDO

Indicação:

Pé diabético infectado.

Técnica:

Exame realizado em aparelho de alto campo (1,5 Tesla) nos planos axial, coronal e sagital, ponderadas em T1, T2 e densidade de prótons, com e sem saturação de gordura. Foi administrado meio de contraste paramagnético (gadolínio) por via intravenosa.

Relatório:

Colapso ósseo no mediopé, com indefinição parcial das estruturas ósseas, com extenso edema da medular óssea regional, associado a desarranjo articular, espessamento capsulossinovial e edema nas partes moles periarticular.

Demais estruturas ósseas e relações articulares no antepé preservadas.

Tendões flexores e extensores com intensidade normal e espessura preservada.

O ligamento de Lisfranc apresenta-se íntegro.

Não se observam modificações significativas nas regiões intermetatársicas distais.

Placas plantares das articulações metatarsófalângicas mostram-se íntegras.

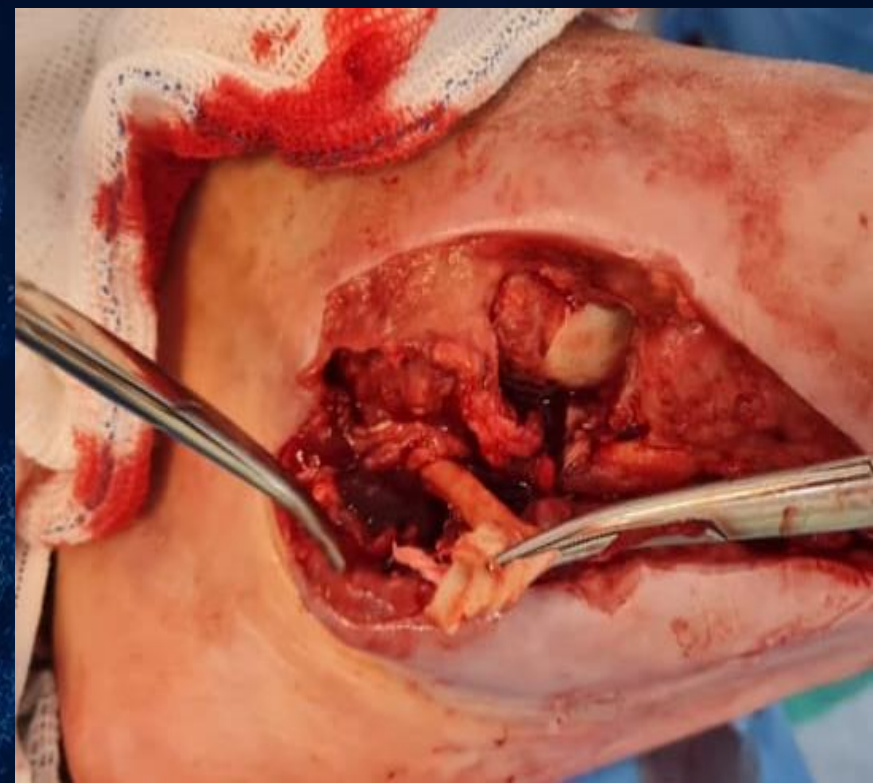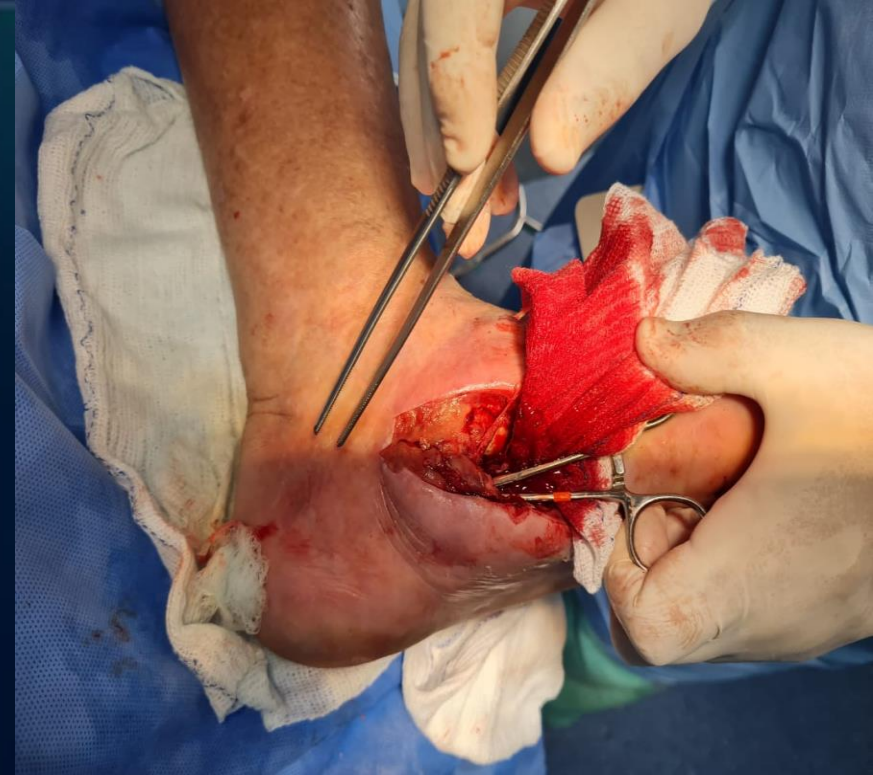
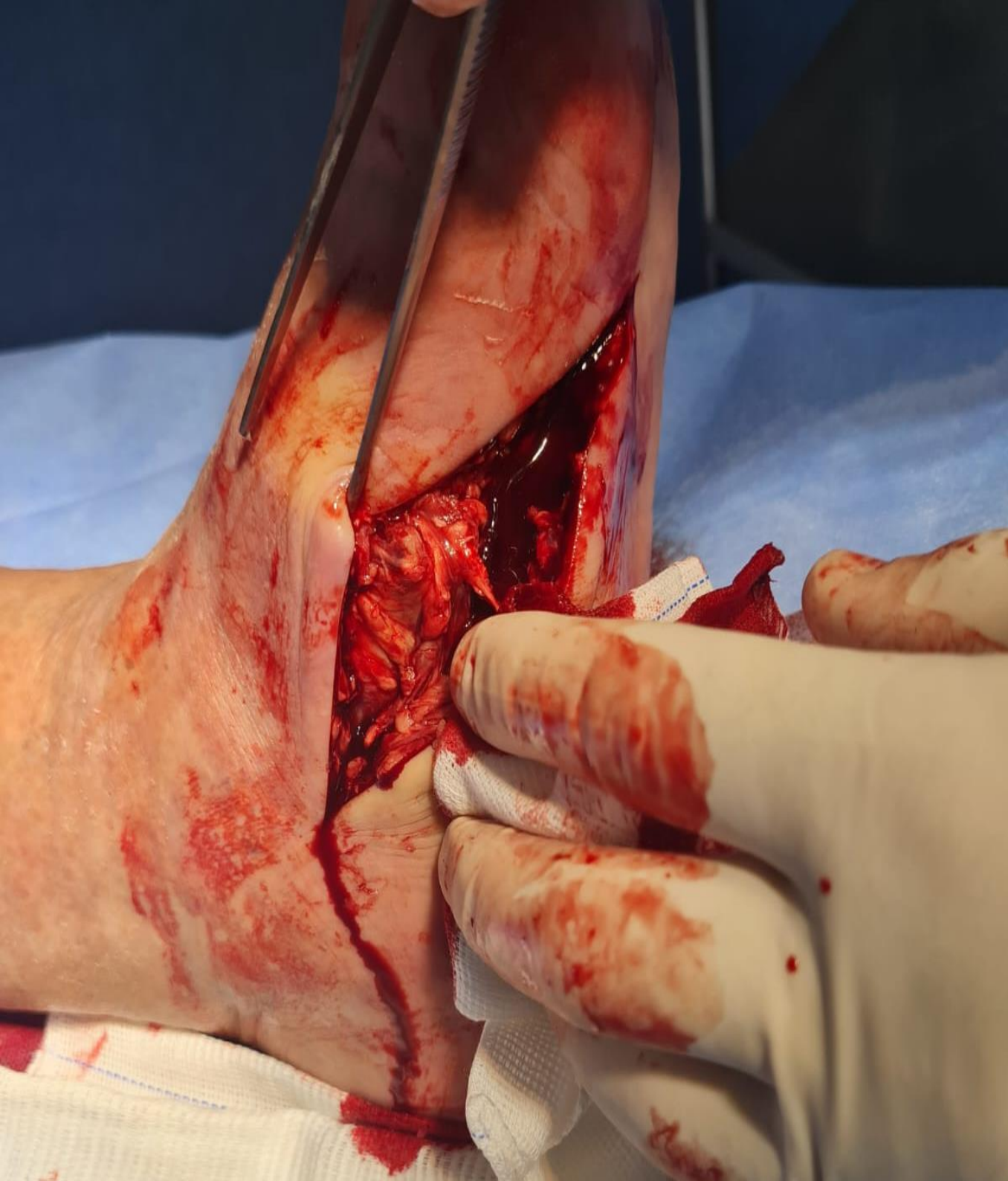
Musculatura intrínseca do antepé com intensidade de sinal e trofismo preservados.

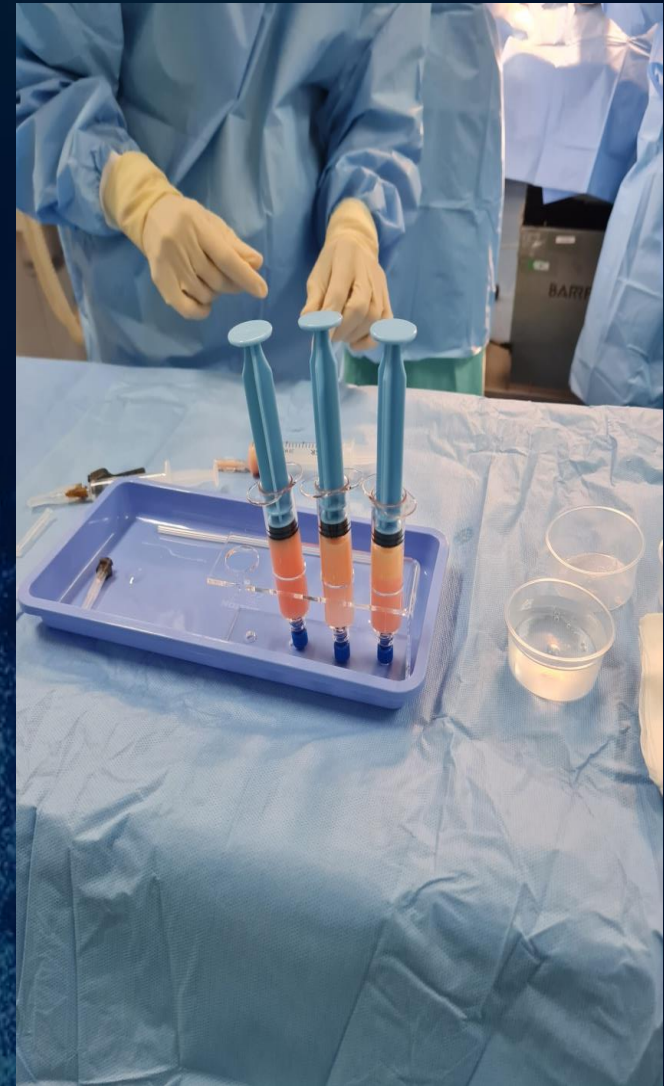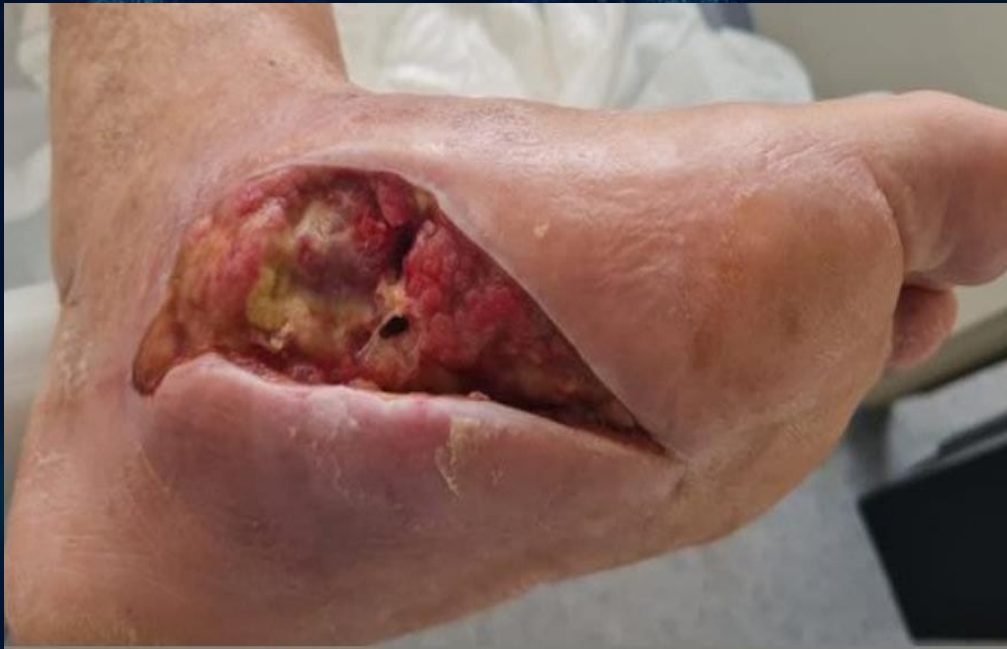Edema na tela subcutânea regional.

Impressão:

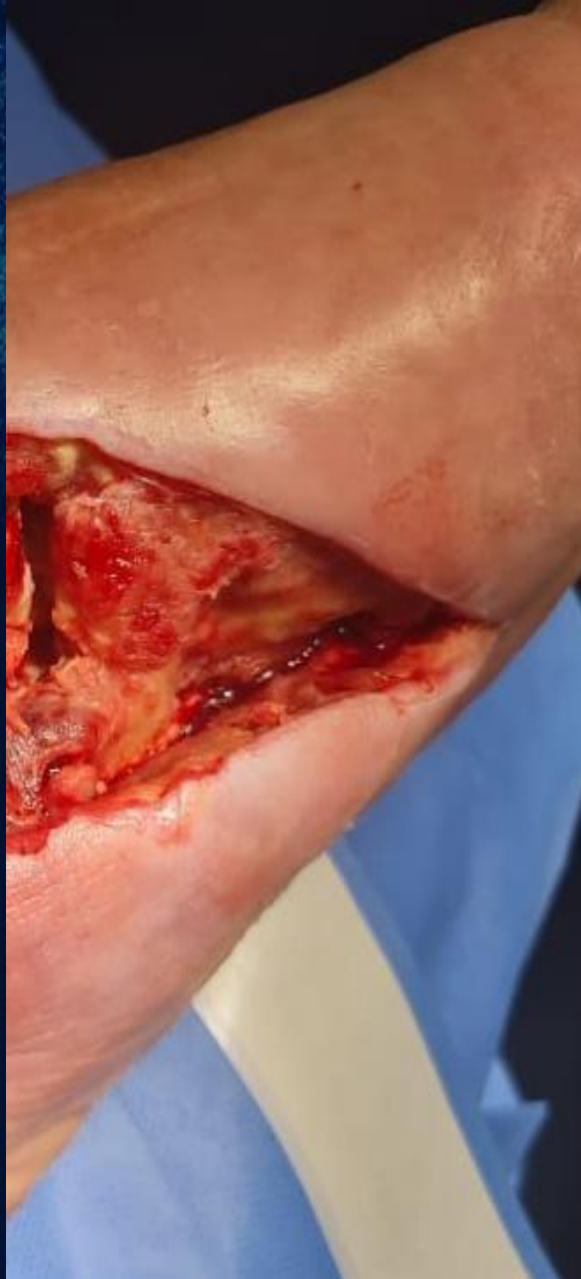Colapso ósseo no mediopé, com desarranjo articular e sinovite difusa, inferindo osteomielite.

Dr. Rodrigo Assmann de Oliveira

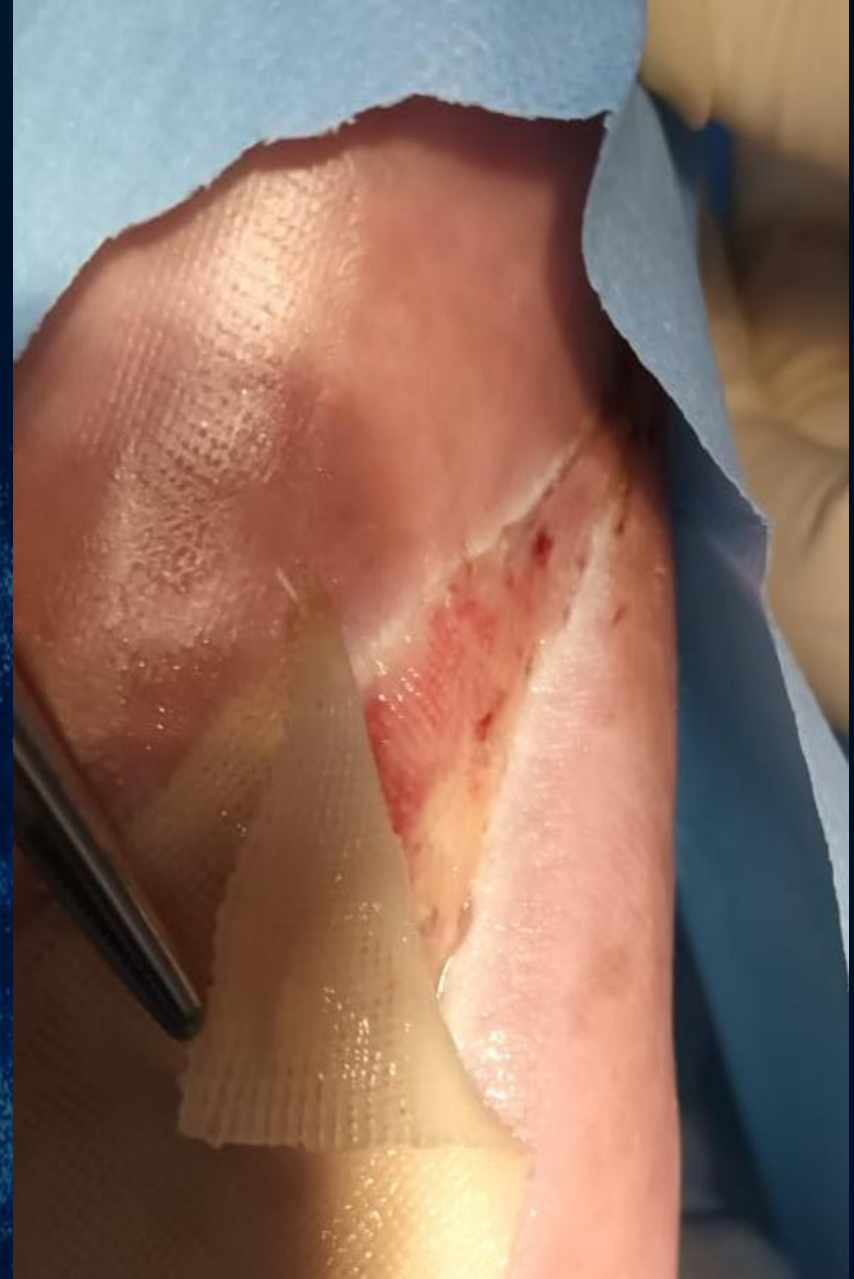


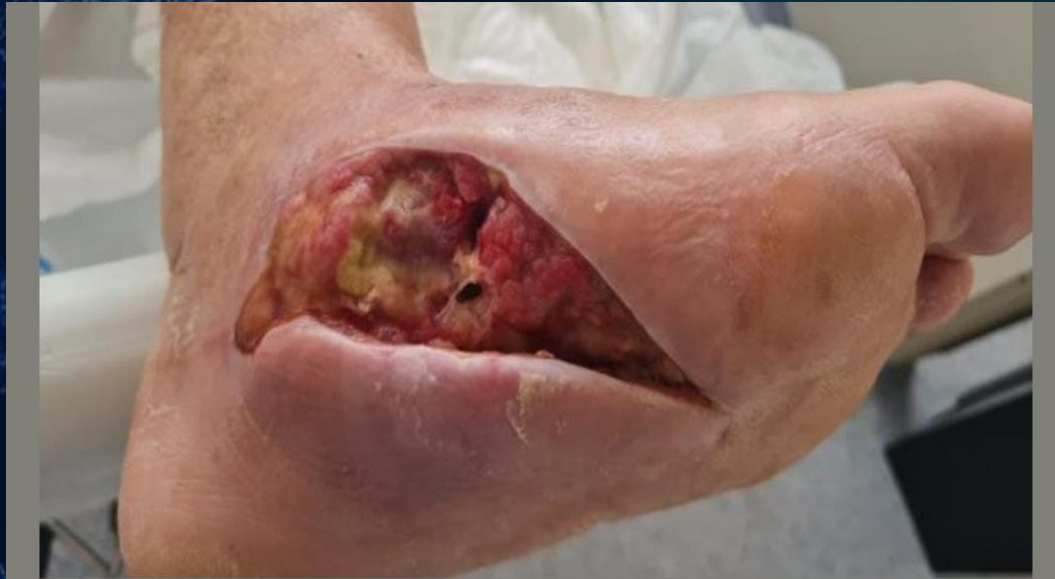
D1

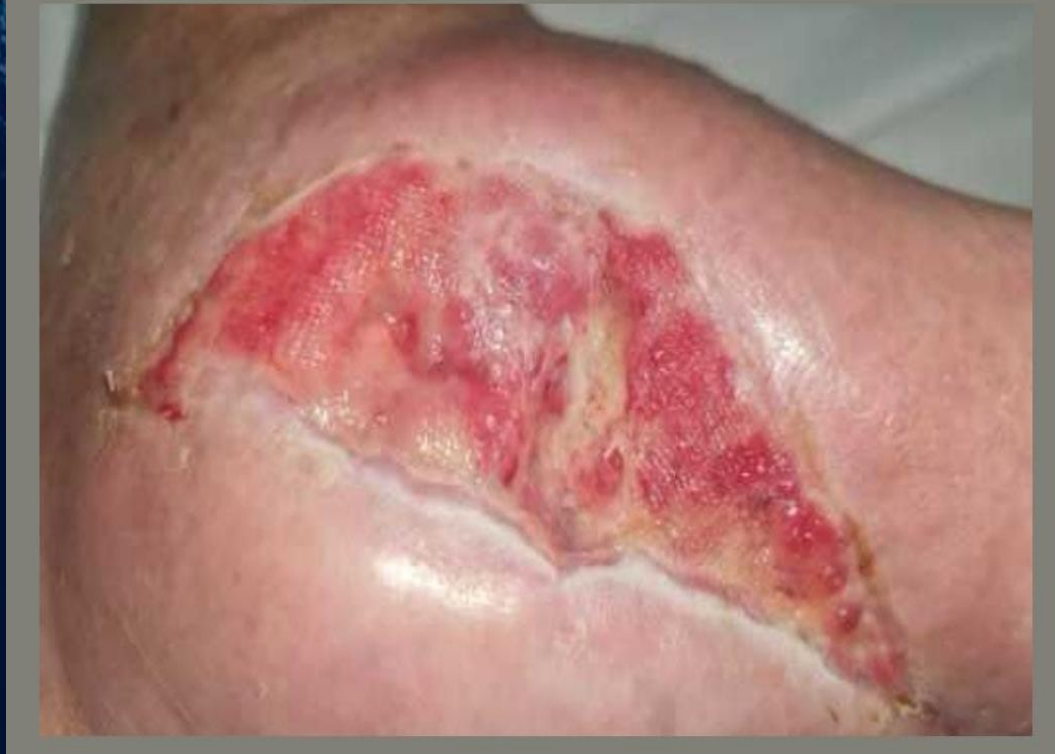

D6





D12



CT

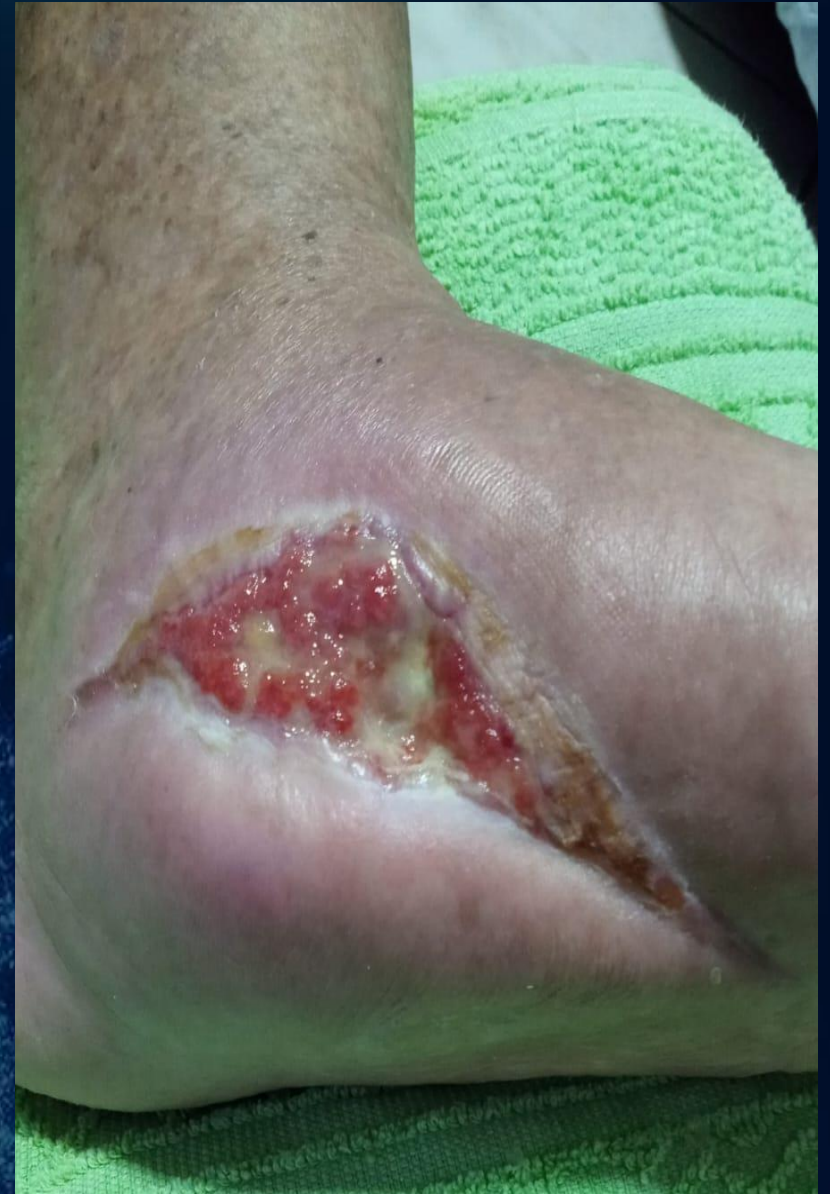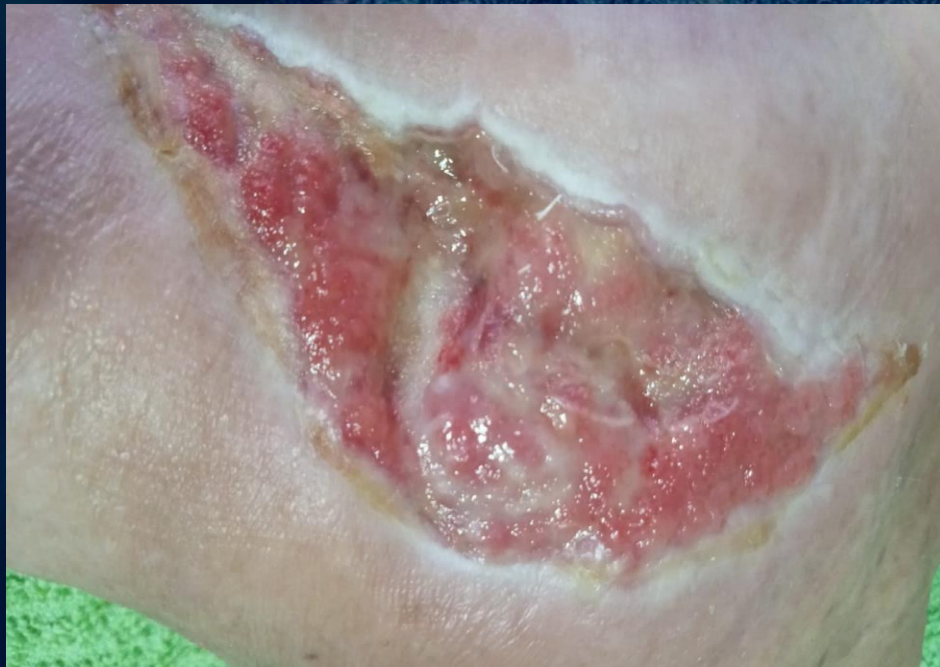Técnica:

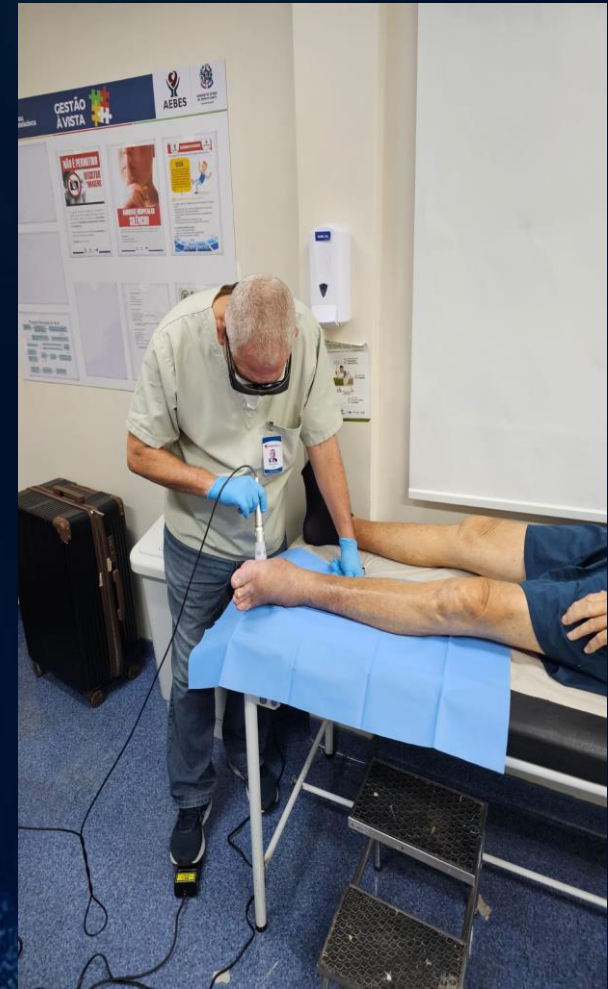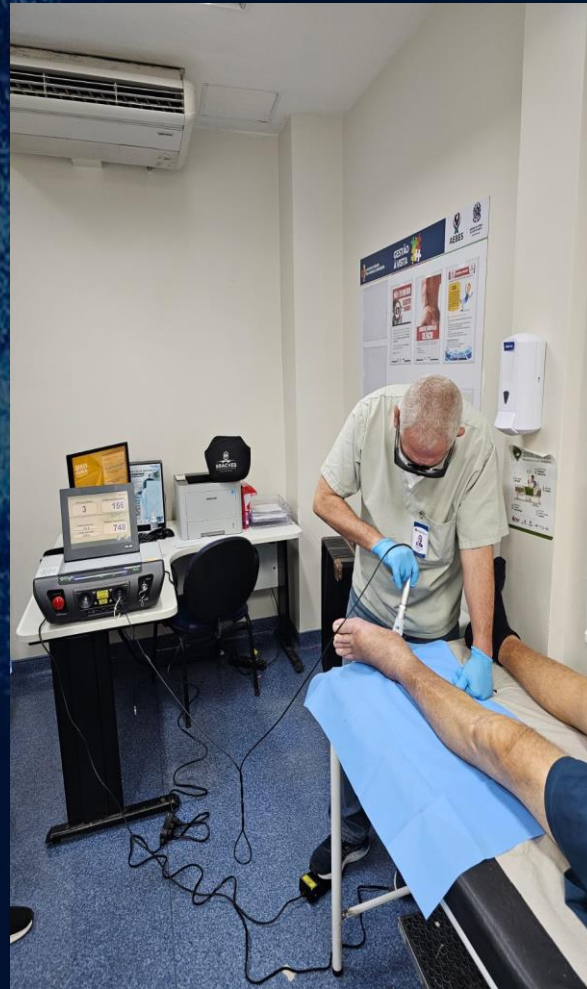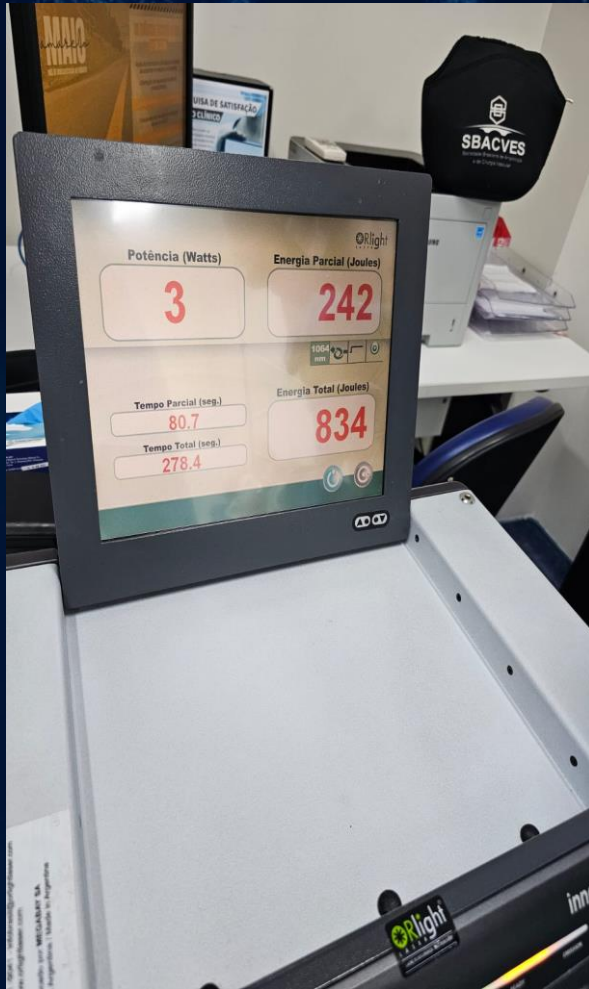
Exame realizado em aparelho multidetector, com posteriores reconstruções multiplanares, sem a administração endovenosa do meio de contraste.

Relatório:

Em comparação ao exame anterior realizado no dia 27/08/2023, observa-se:

Alterações pós cirúrgicas caracterizadas por solução de continuidade na pele e em planos mioadiposos superficiais e profundos na face medial do pé, acompanhados de pequenas vesículas gasosas e infiltração edematosa de partes moles. Houve ressecção de fragmentos ósseos/ossificações em partes moles nessa topografia. Não foram observadas coleções passíveis de drenagem ao método/protocolo proposto.



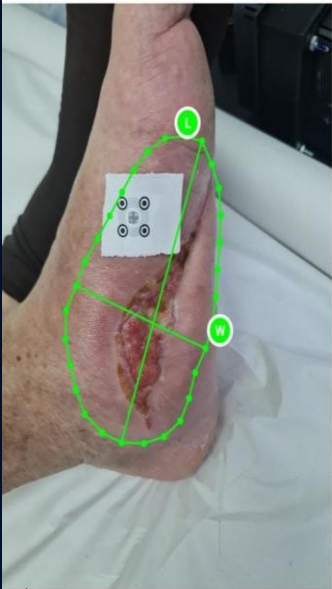




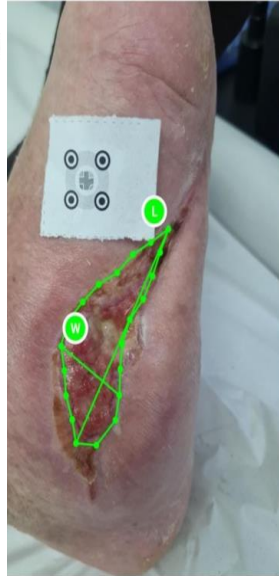Measurement Report



Measurement Report



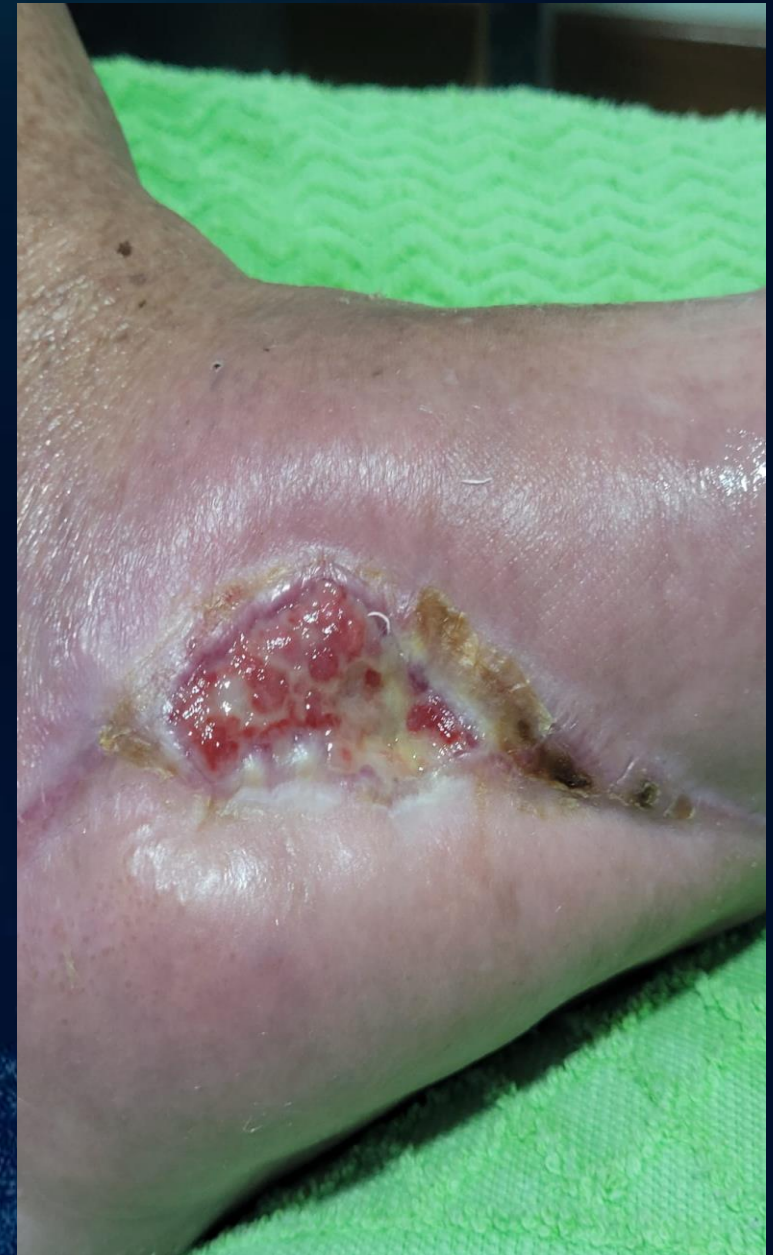Data: AM-06-14 11: 08
Área: 58,74
Largura: 6,49
Comprimento: 11,77
Circunferência: 29,49

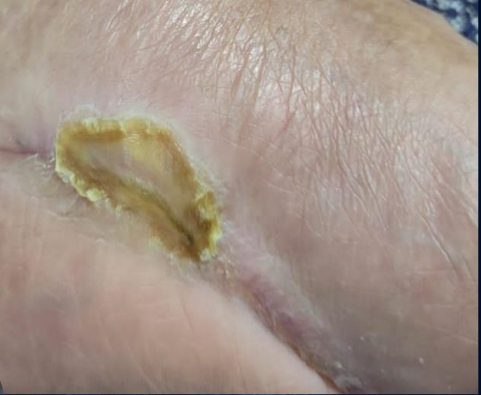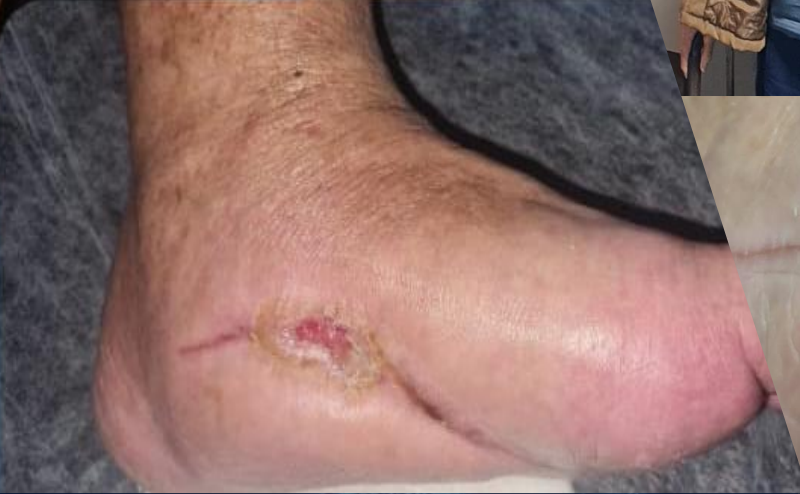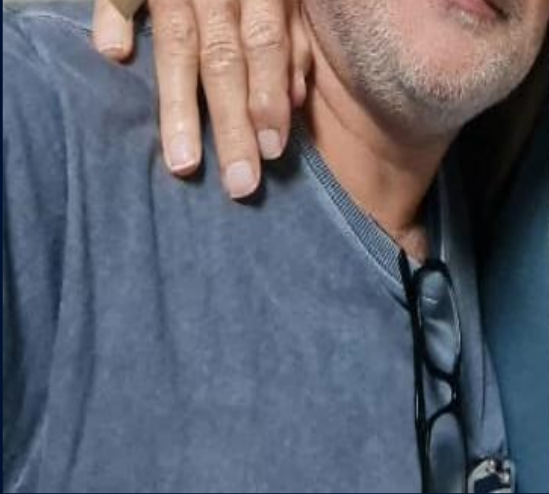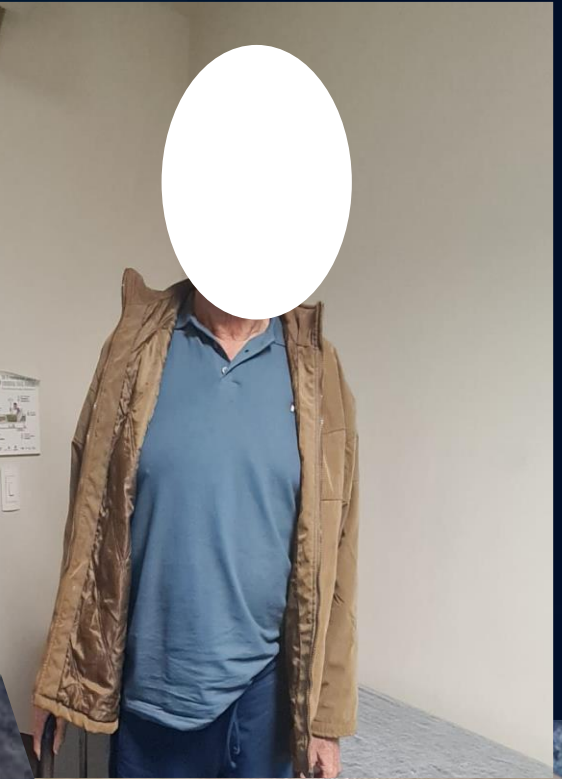


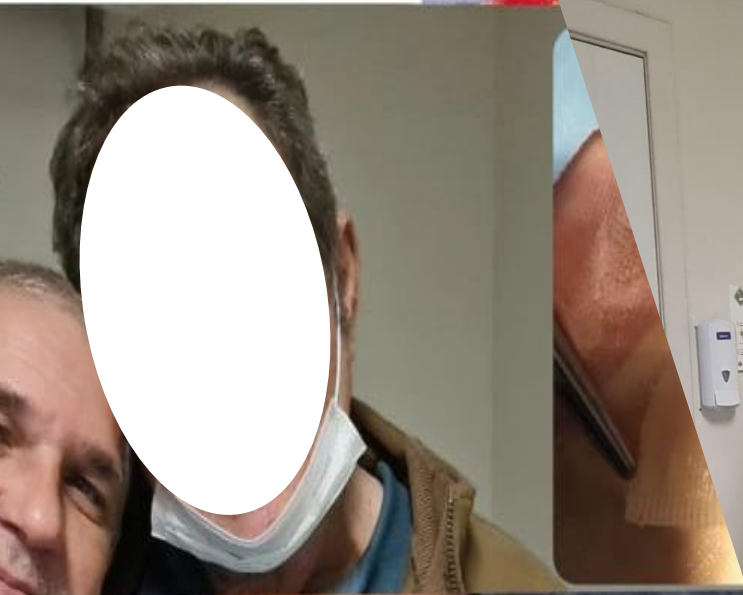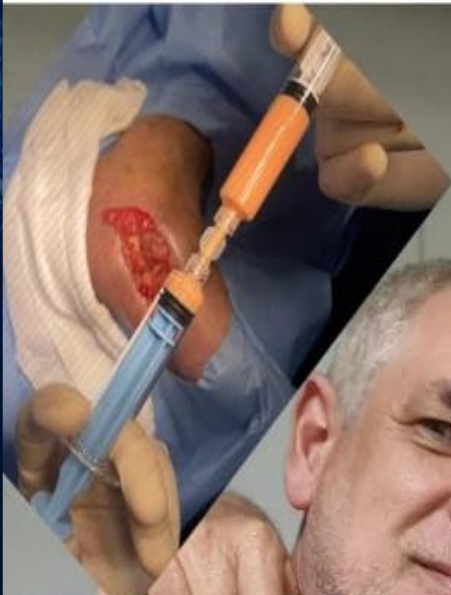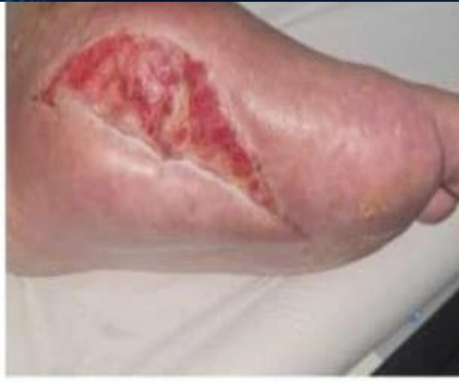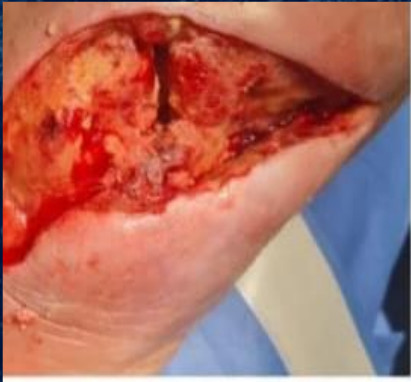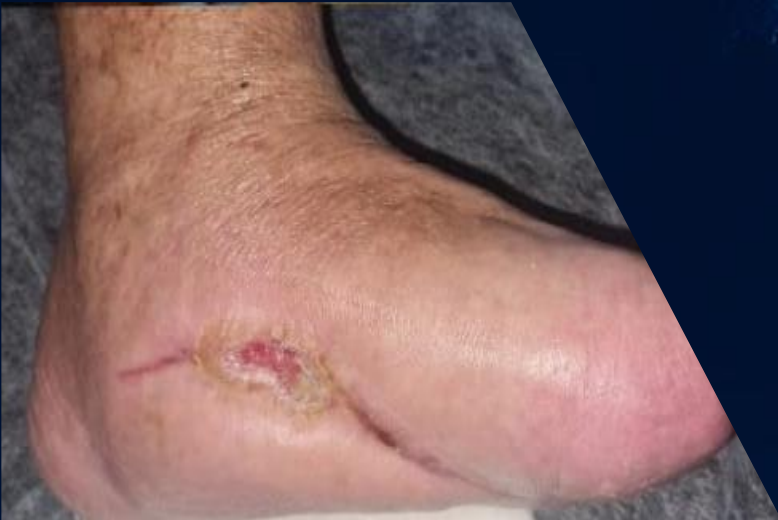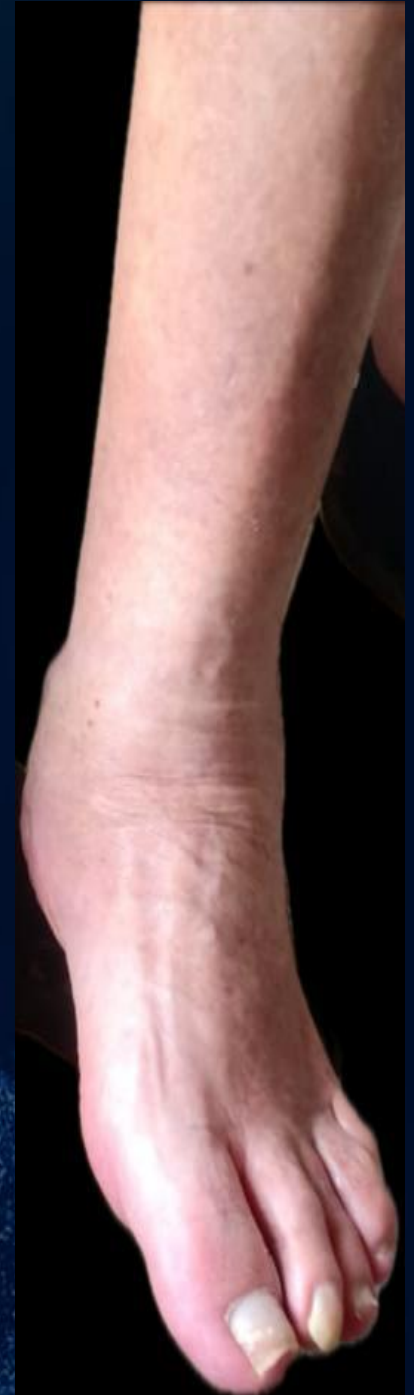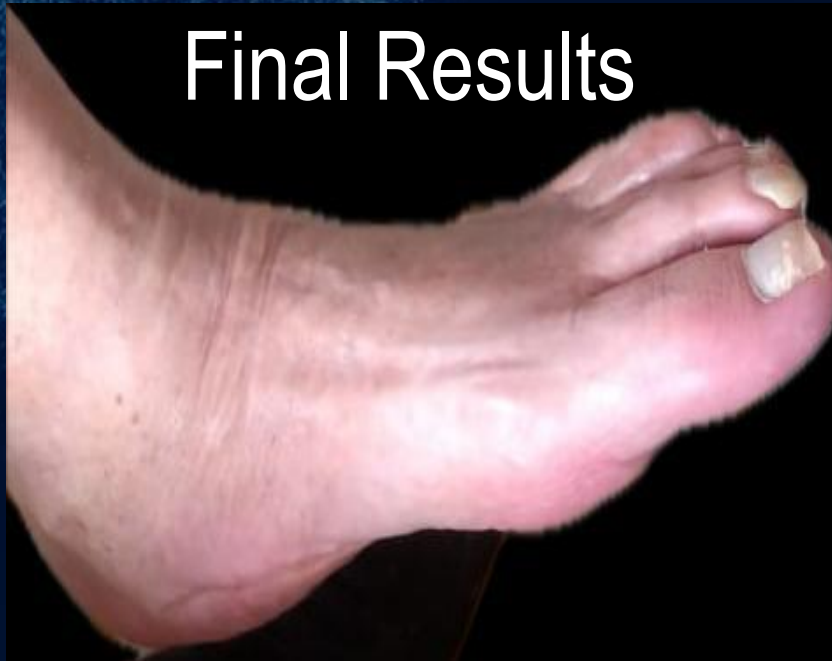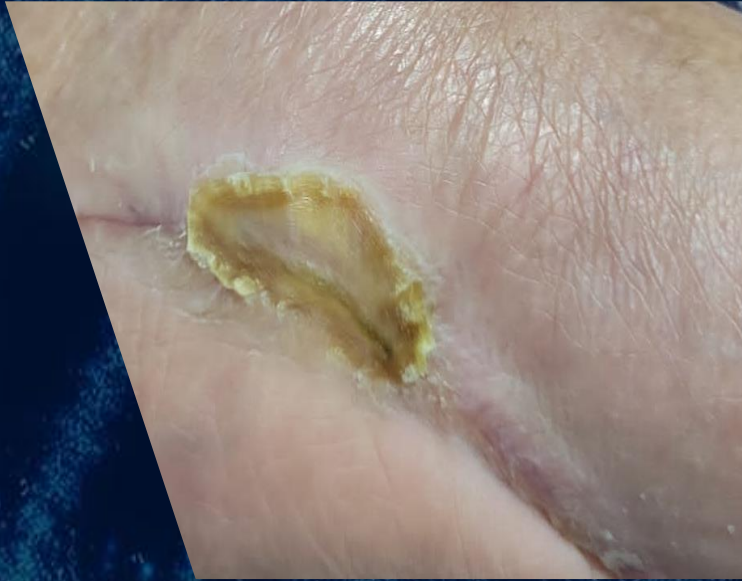Data: AM-06-14
Área: 7,96
Largura: 2,12
Comprimento: 6,2
Circunferência: 13,96

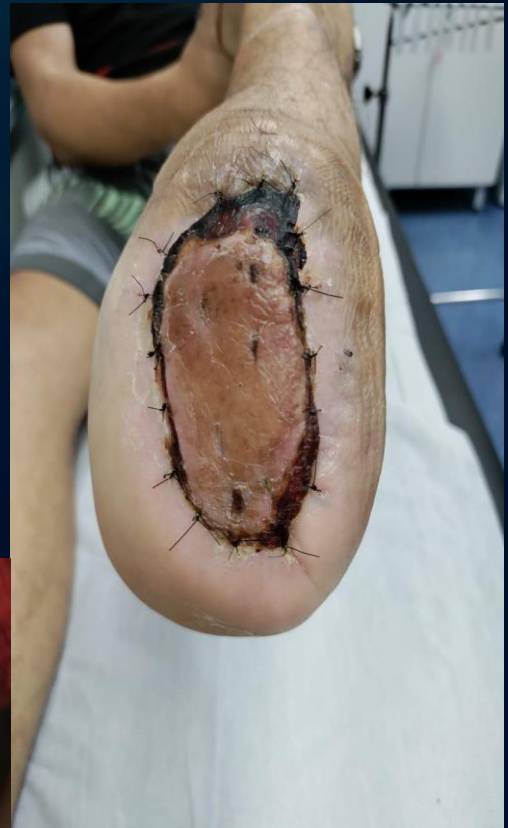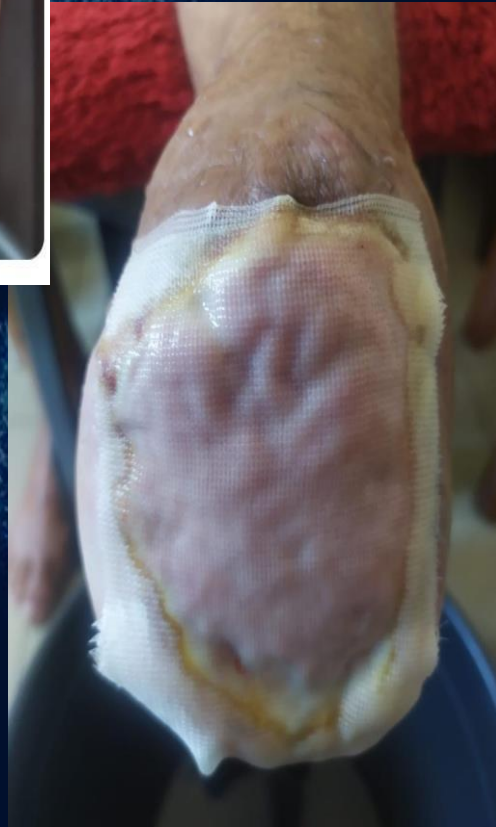
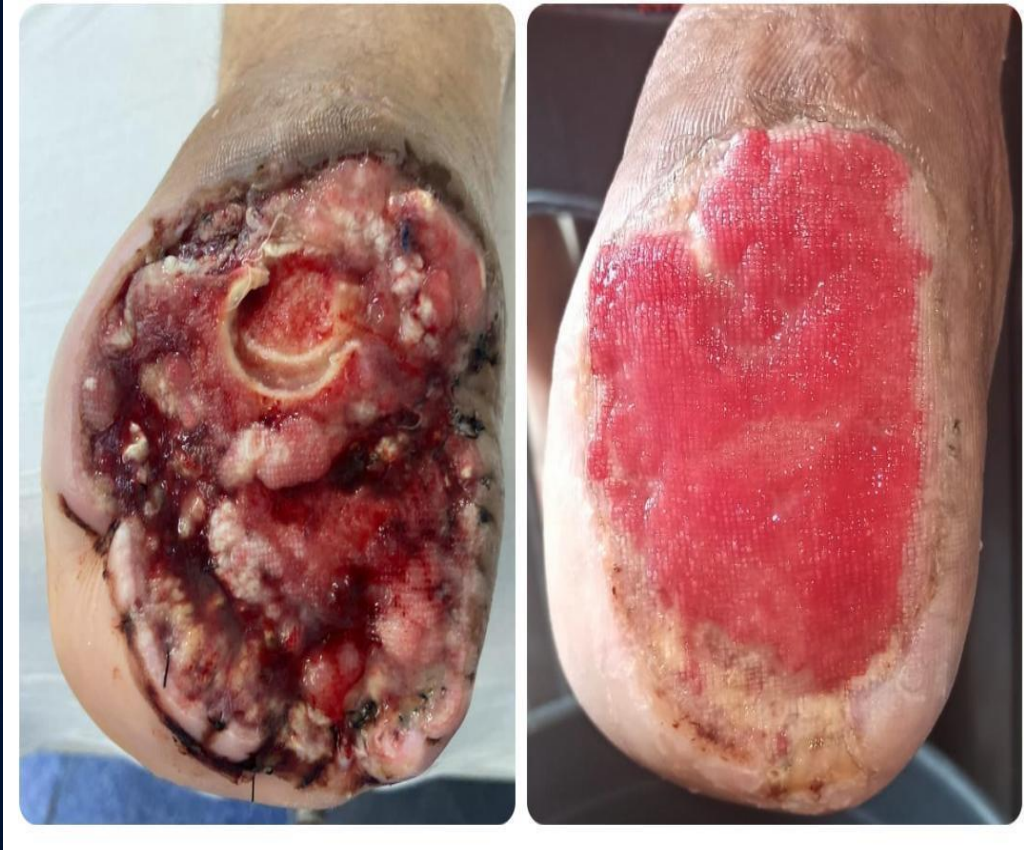Comment: AAM, D20 LASER

Comment: AAM, DM SEFFICARE D34 E LASER D20 NEUROPATIA



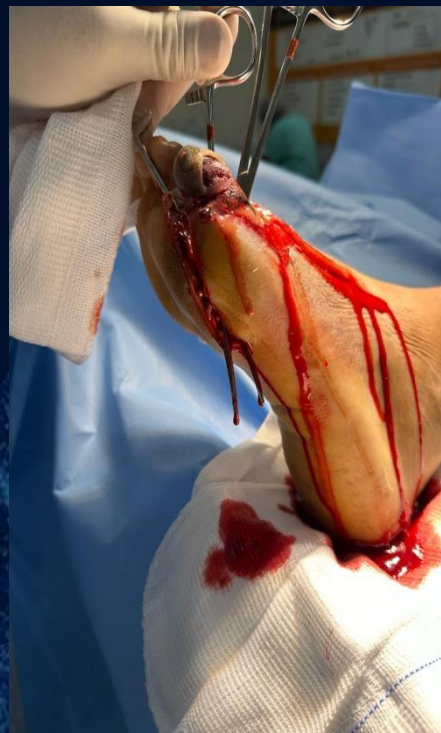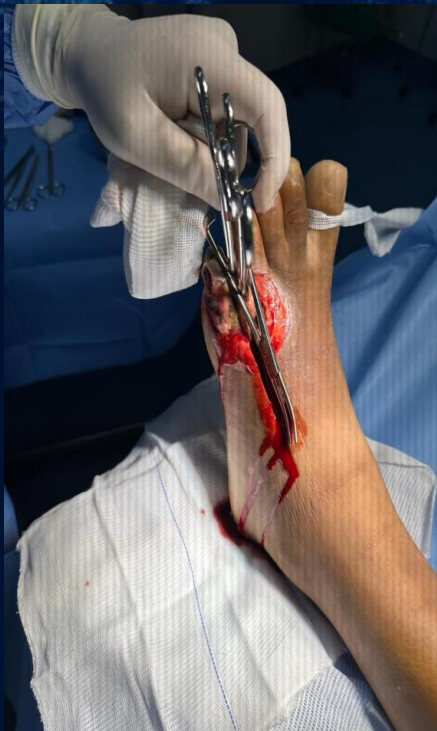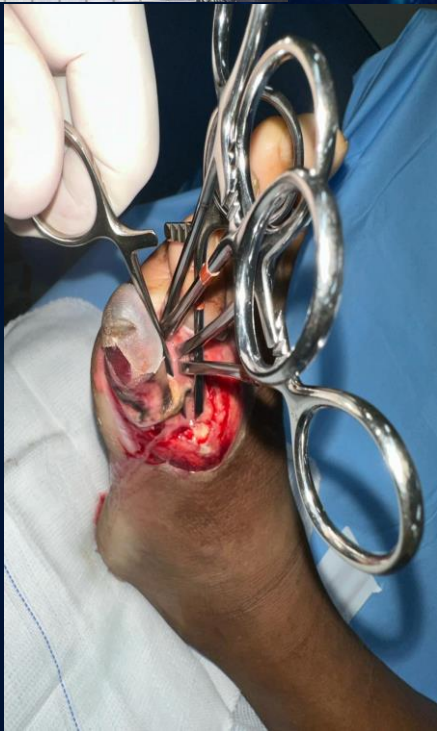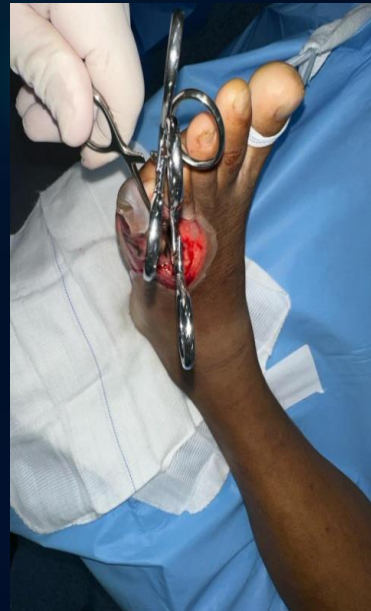



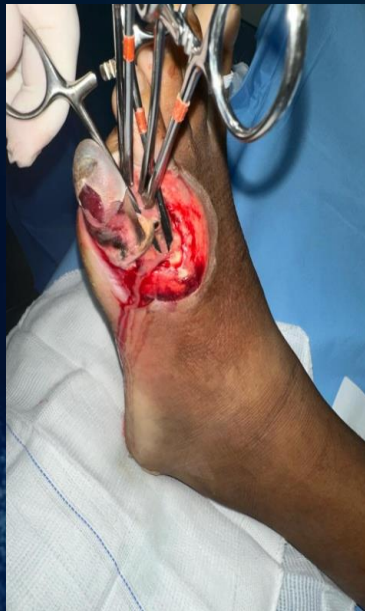
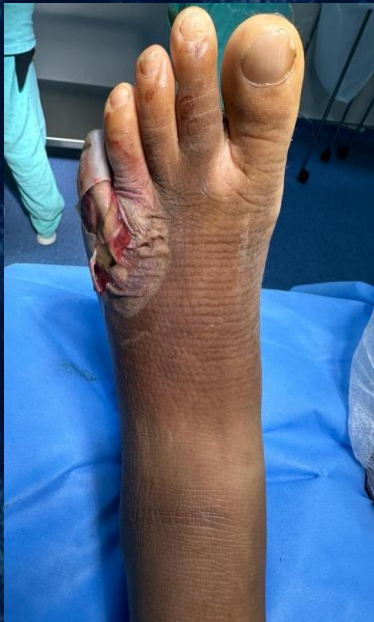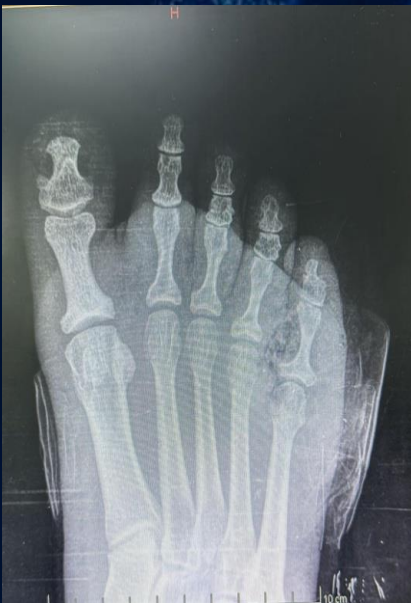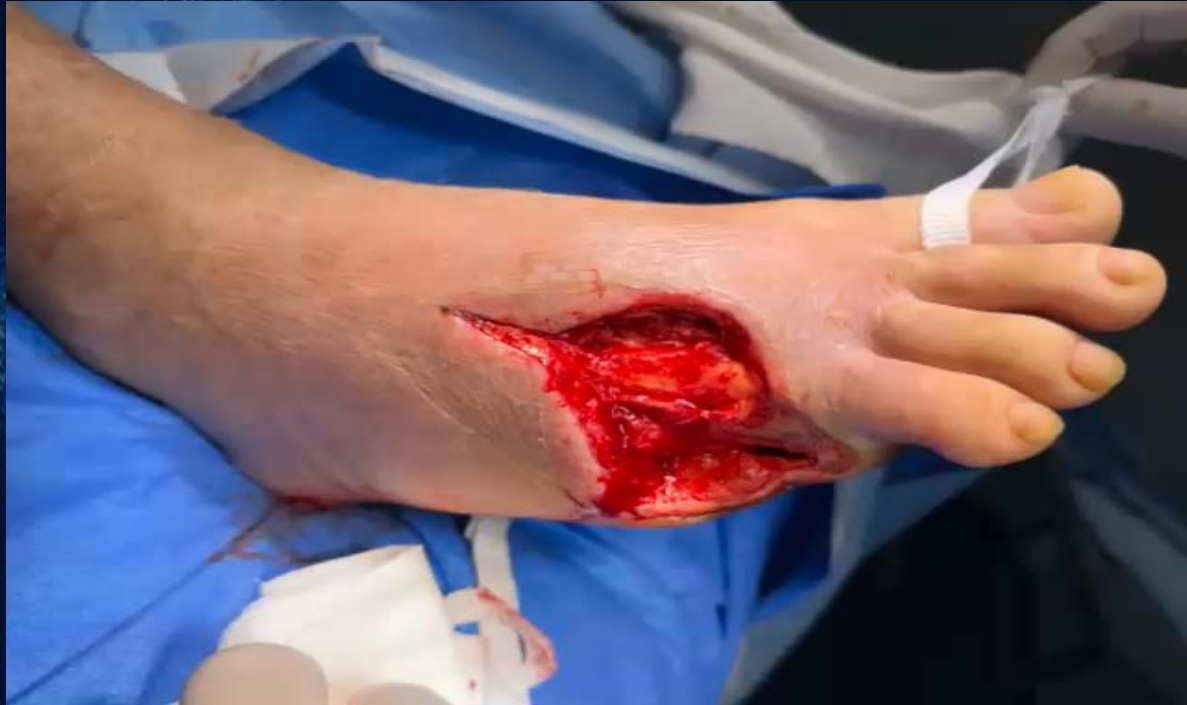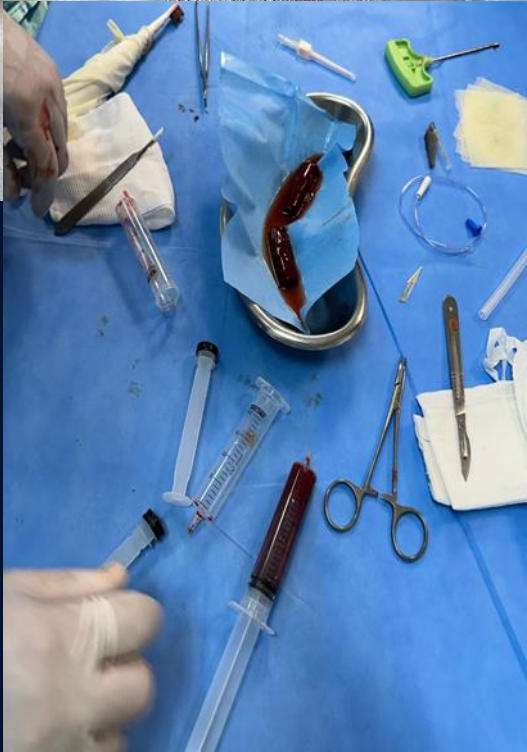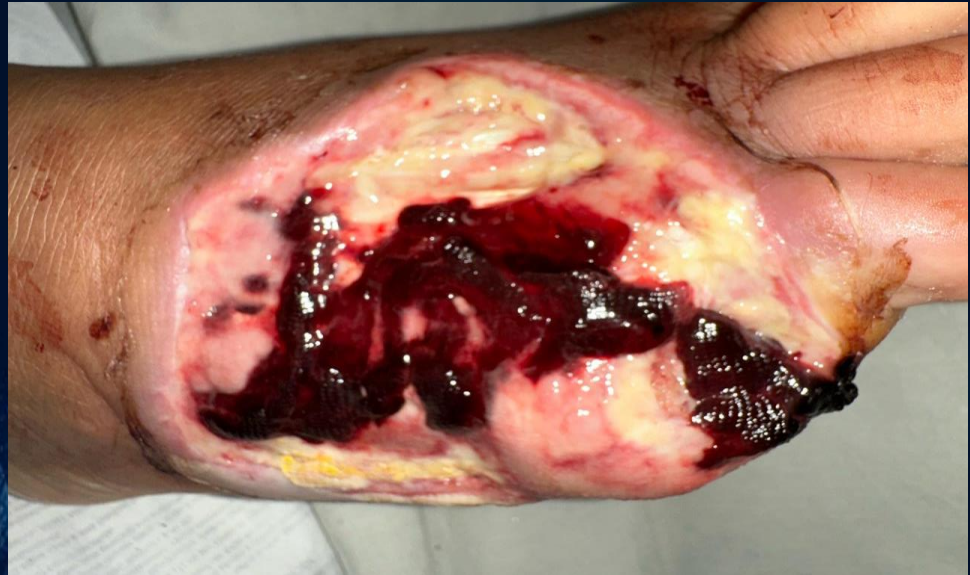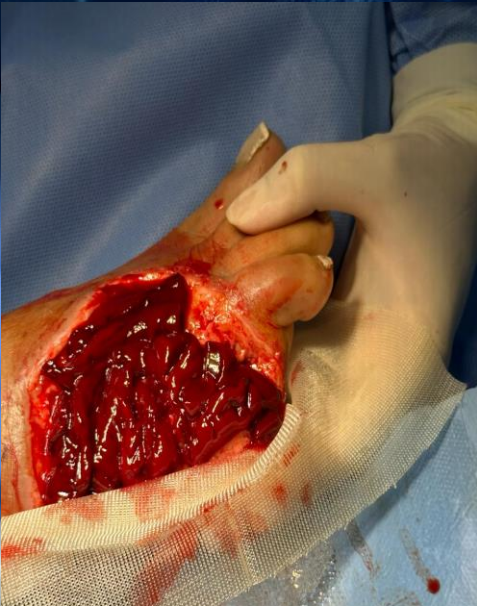


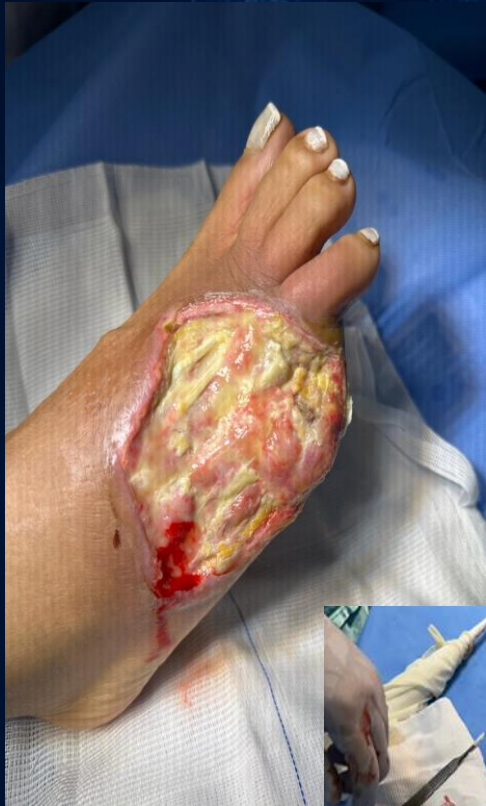Debridement

Compartment-based approach case



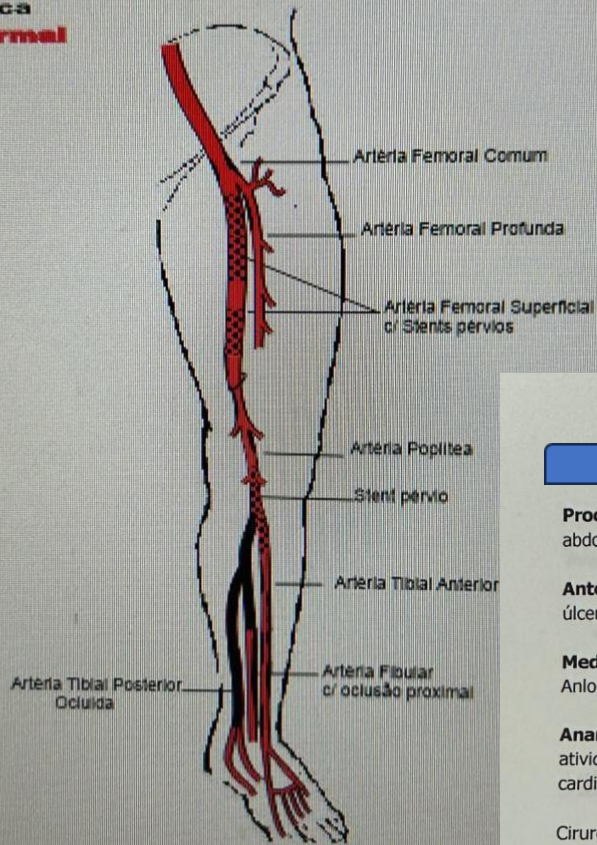
Debridement with Bone Marrow Aspiration (BMA)



Data: 22.11.23

Médico solicitante: Dr. Roberto Gomide

● - Placa
● - Normal



Case 85

06/03

RISCO CIRÚRGICO CARDIOLÓGICO

Procedimento proposto: enxerto em membro inferior esquerdo (área doadora abdominal)

Antecedentes patológicos pessoais: HAS, arritmia, angioplastia vascular prévia, úlcera crônica, DAOP (múltiplas angioplastias prévias, a última há 6 meses).

Medicações em uso contínuo: AAS 100 mg, Losartana 50 mg, Thiocacid, Anlodipino, Novanlo (?).

Anamnese: Paciente assintomática do ponto de vista cardiovascular, porém não realiza atividades físicas habitualmente. Relata tolerar esforços do dia a dia. Nega antecedentes cardiovasculares graves.

Cirurgias prévias: angioplastias, cirurgia vascular venosa, histerectomia, apendicectomia – sem intercorrências.

Capacidade funcional estimada pela entrevista: 5 METs (andar em alicives, subir escadas).

Exame Físico:

PA: 137 x 76 mmHg; FC: 86 bpm

SNC: glasgow 15, sem déficits focais ou sinais meníngeos

ACV: ritmo cardíaco regular em 2 tempos, sopro diastólico aórtico.

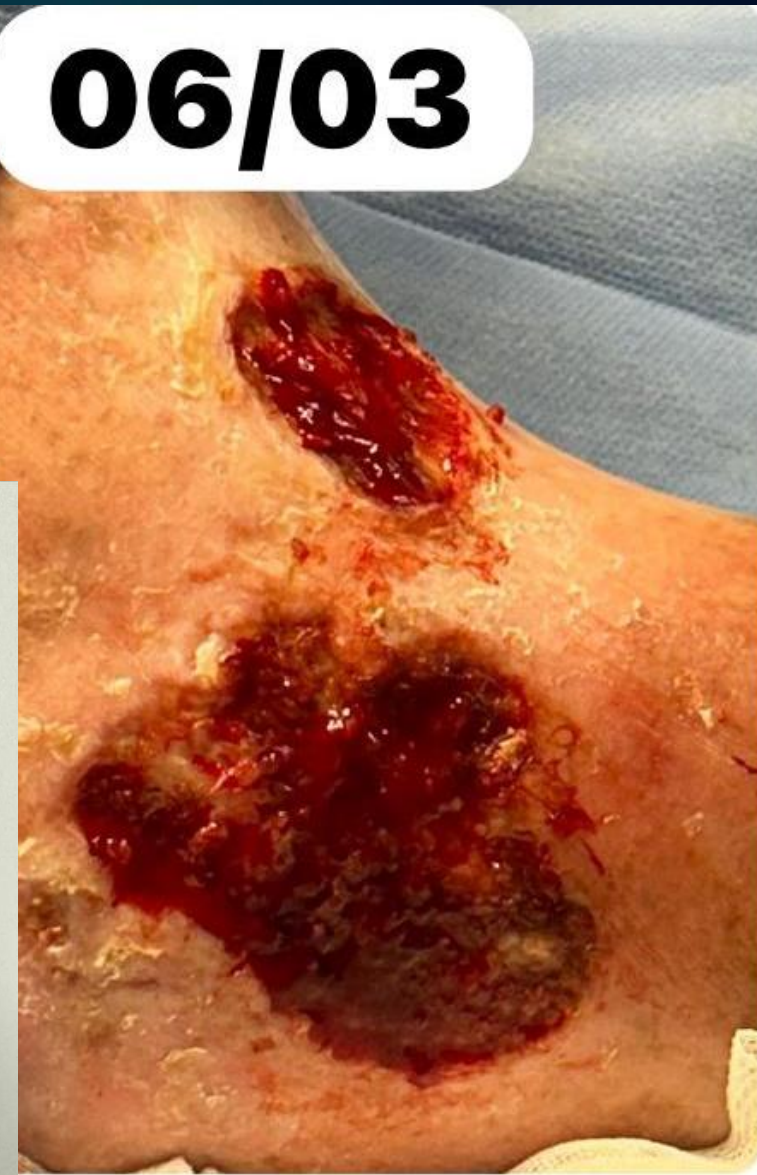AR: MV+, creptos bibasais.

Exames Complementares:

- ECG (28/02/24): RS, eixo normal, sinais de SAD, PR limitrofe.

- Lab (05/02/24): Hb 13, 209 mil plaquetas, Cr 0,91, K 4,3, Na 137. Coagulograma normal, PCR 28, GJ 89, HbA1C 5,4%.

- Ecocardiograma transtorácico: Insuficiência mitral moderada (prolapso), dilatação moderada do átrio esquerdo, disfunção diastólica grau II, função sistólica biventricular preservada.



[Convênio: PARTICULAR | Código do Exame: 28.06.030-4]

Exame: FATOR REUMATOIDE

Material: SORO | Método: Aglutinação

Resultado

Resultado.....: **< 10** UI/mL

Legenda aplicável para valores numéricos

Pesquisa de Autoanticorpos Anticélulas (FAN Hep-2)

RESULTADO

Núcleo Não Reagente

Nucleolo Não Reagente

Citoplasma Não Reagente

Aparelho Mitótico Não Reagente

Placa Metafásica Cromossômica Não Reagente

(Método: I)

Diluição de triagem de 1/80, conforme recomendação do Consenso Brasileiro para Detecção Liberado por: Jacqueline Iris Freires de Moura - CRBM 27877 (06/02/2024 - 05:22 BRT) Responsável: Nádia Moreira P. de Carvalho CRF-SP 95475

RESULTADO

Vitamina C 0,5 mg/dL

Exame: FERRITINA

Material: SORO | Método: Eletroquimioluminescência

Resultado.....: **29,9** ug/L

Hash (Validador): fcGWSW

Valor Referencial

Mulheres: 20 a

Homens: 30 a 22

[Convênio: PARTICULAR | Código do Exame: 28.06.087-3]

Exame: PROTEINA C REATIVA

Material: SORO | Método: Aglutinação, Turbidimetria

Resultado

Resultado.....: **28,46** mg/L

Assinado Por: Dra. Alliny Portillo de Lima Nascimento
CRF-GO: 6491

[Convênio: PARTICULAR | Código do Exame: 28.04.093-7] [Coleta: 23/02/2024 06:51 | Liberado: 26/02/2024 14:47]

Exame: HEMOGLOBINA GLICADA

Material: SANGUE TOTAL - EDTA | Método: Imunoensaio Turbidimétrico de Inibição

Resultado

Hemoglobina Glicada ..: **5,4** %

Glicose Média Estimada: **109,0** mg/dL

Hash (Validador): VHG=NF0ML5M3Z2Kerpp0YIC96JHEVL0Hq1KedpM1dMS=

Valor(es) de referência:

Hemoglobina Glicada - Hb Salc

Normal: Inferior a 5,7%

Risco aumentado para Diabetes Mellitus: 5,7 a 6,4%

Diabete Mellitus: Igual ou superior a 6,5%

Nota:

Na ausência de hiperglicemia inequívoca, o diagnóstico de diabetes requer dois testes alterados (glicemia de jejum, curva glicêmica ou hemoglobina glicada) na mesma amostra ou em amostras de dias diferentes.

A Associação Americana de Diabetes recomenda como meta para o tratamento de pacientes diabéticos resultados de HbA1c iguais ou inferiores a 7%.

Conforme recomendado pela American Diabetes Association (ADA) e European Association for the Study of Diabetes (EASD), estamos liberando o cálculo da glicose média estimada (eAG). Este cálculo é obtido a partir do valor de HbA1c através de uma fórmula matemática baseada em uma relação linear entre os níveis de HbA1c e a glicose média sanguínea.

American Diabetes Association - Standards of Medical Care in Diabetes 2019. Diabetes Care 2019; 42, (Supplement 1): S13-S28.

Assinado Por: Dra. Alliny Portillo de Lima Nascimento
CRF-GO: 6491

[Convênio: PARTICULAR | Código do Exame: 28.01.080-9] [Coleta: 02/02/2024 07:45 | Liberado: 02/02/2024 15:26]

Exame: FERRO

Material: SORO | Método: Colorimétrico

Resultado.....: **127,4** ug/dL

Hash (Validador): Xq2aaERm/vIE/y1VQp76K/QTC=

Valor Referencial

Homens: 59 a 158 ug/dL

Mulheres: 37 a 145 ug/dL

Nota:

A concentração sérica do ferro pode sofrer pequenas alterações ao longo do dia (variação circadiana), portanto sua análise deve ser realizada em conjunto com outros marcadores do metabolismo do ferro.

Doutor(a): JALYS FRAGA

[Convênio: PARTICULAR | Código do Exame: 28.01.054-0]

Exame: CREATININA

Material: SORO | Método: CINÉTICO - JAFFÉ

Resultado

CREATININA.....: **0,91** mg/dL

eGFR Afro Descendente.: **67,15** mL/min/1,73m²

Legenda aplicável para valores numéricos

Eletroforese de Proteínas

RESULTADO

Proteínas Totais **100** % **7,0** g/dL

Relação A/G **1,26**

Albumina **55,8** % **3,89** g/dL

[Convênio: PARTICULAR | Código do Exame: 28.01.037-1]

Exame: TRANSAMINASE GLUTAMICO PIRUVICA, TGP, ALT

Material: SORO

Resultado

TGP.....: **15,6** U/L

ALT.....: **15,6** U/L

Hash (Validador): Tsr045cy8BAKAs3yAcas805y8R7W0kult65Vg800GP1=

Valor Referencial

Mulheres: Até 31,0 U/L

Homens: Até 41,0 U/L

Assinado Por: Dra. Alliny Portillo de Lima Nascimento
CRF-GO: 6491

[Convênio: PARTICULAR | Código do Exame: 28.04.049-0] [Coleta: 23/02/2024 06:51 | Liberado: 23/02/2024 15:26]

Exame: HEMOSSEDIMENTACAO, VHS

Material: SANGUE TOTAL - EDTA | Método: Westergreen

Resultado

VHS.....: **16** mm/h

Hash (Validador): Ichy1REmWqWv1v3p0iFzXY/j+1V51Ru301foKrsSG=

Valor Referencial

(-) Indicador (-)

Resultado.....: **16** mm/h

Assinado Por: Dra. Alliny Portillo de Lima Nascimento
CRF-GO: 6491

RESULTADO

Potássio **4,30** mmol/L

Sódio **137,8** mmol/L

Vitamina A **0,2** mg/L

Referência bibliográfica

Burtis, CA, Ashwood, ER, Bruns, DE. Tetz Textbook of Clinical Chemistry and Molecular Diagnosis. 4o Ed. Saint Louis: Elsevier Saunders, 2006.

Soldin, SJ, Brugnara, G, Wong, EC, Solbin, OP. Pediatric Reference Intervals. 7a. Ed. Washington DC: AACCPress, 2011.

Liberado por: Luiz Gustavo Martins e Sousa CRBM-GO: 1309 (02/02/2024 - 20:16 BRT) Responsável: Luiz Gustavo Martins e Sousa CRBM-GO 1309

Liberado por: Renato José Teixeira - CRBM 19991 (03/02/2024 - 01:59 BRT) Responsável: Luiz Gustavo Martins e Sousa CRBM-GO 1309

[Convênio: PARTICULAR | Código do Exame: 28.04.013-9] [Coleta: 23/02/2024 06:51 | Liberado: 23/02/2024 15:26]

Exame: COAGULOGRAMA COMPLETO

Material: SANGUE EDTA + PLASMA CITRATADO | Método: Análise Macroscópica, microscópica e química, Coagulométrico automático

Resultado

Contagem de Plaquetas.: **194.000** /mm³

Tempo de Protrombina

Plasma Normal (N).....: **12,00** segundo(s)

Plasma do Paciente (P): **11,70** segundo(s)

Relação P/N.....: **0,97** 1,00 a 1,30

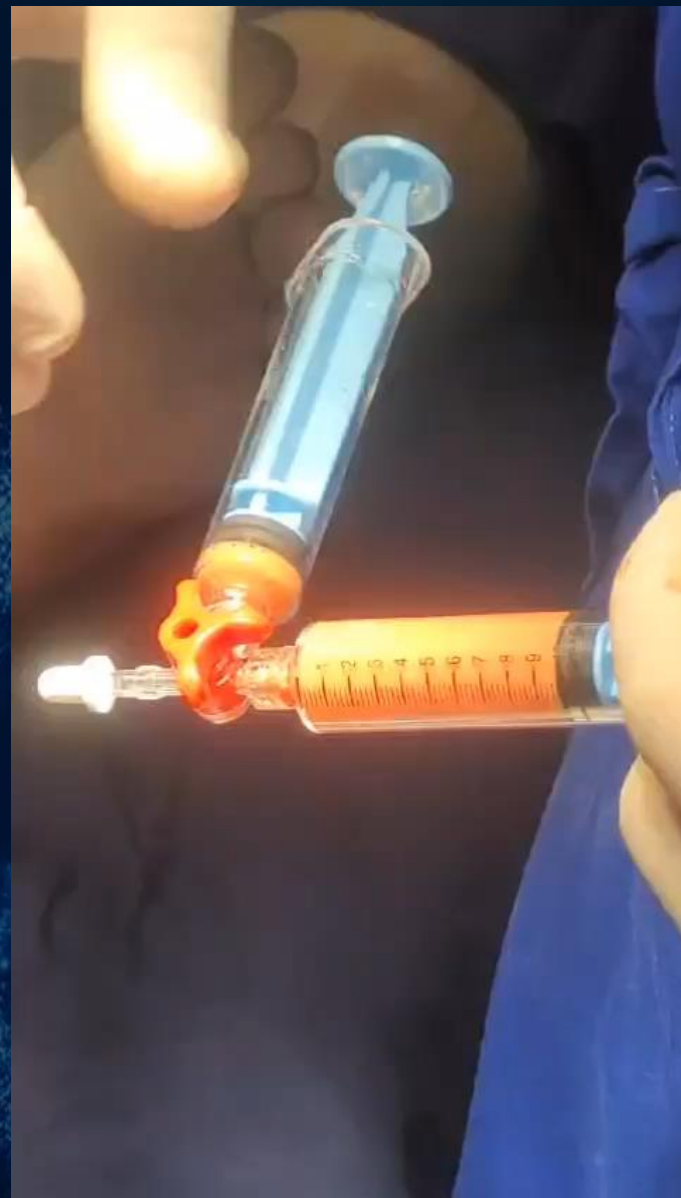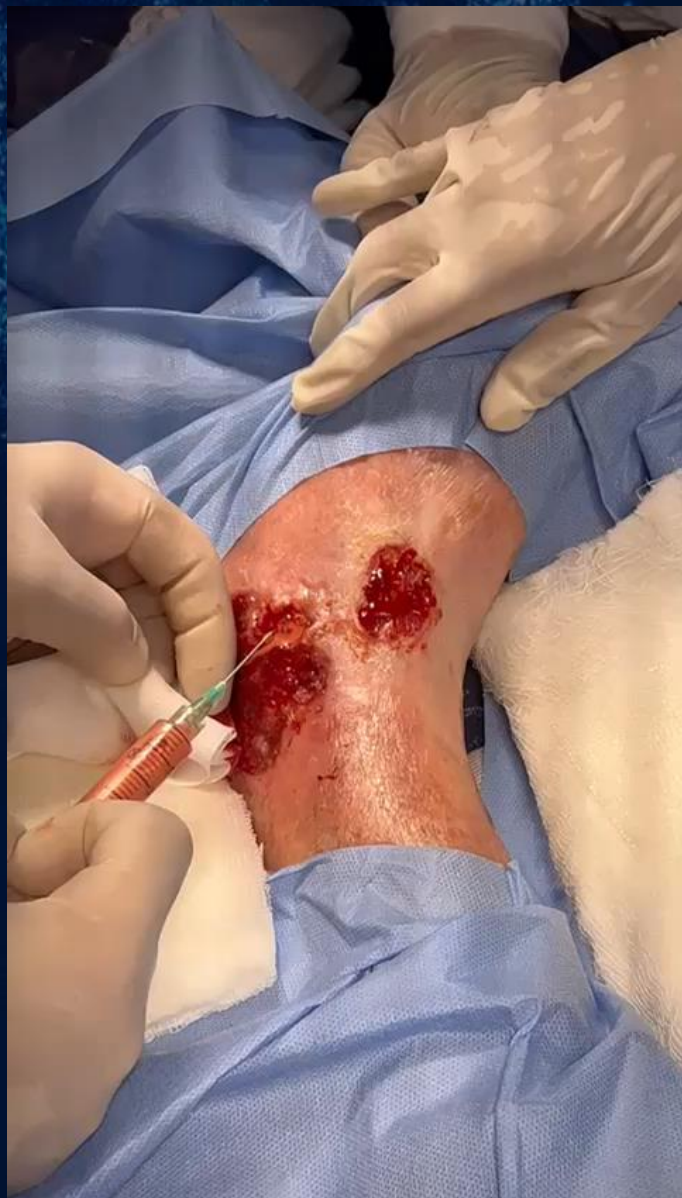Atividade.....: **103** %

RNI.....: **0,97**

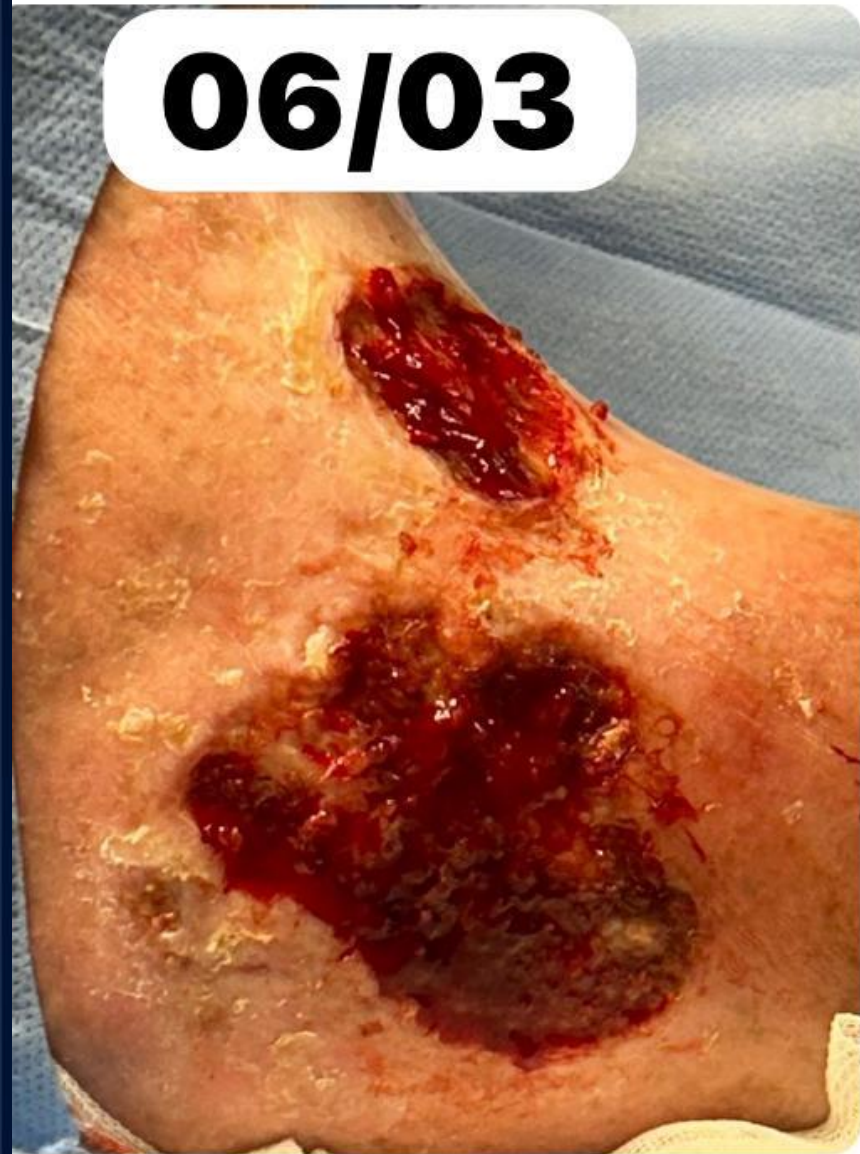Tempo de Tromboplastina Parcial Ativado

Plasma do Paciente (P): **34,64** segundo(s) 23,00 a 45,00 segundos

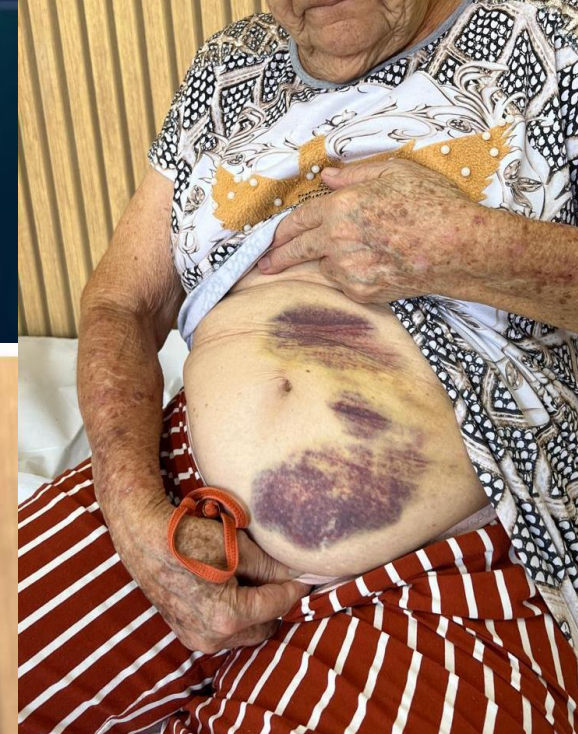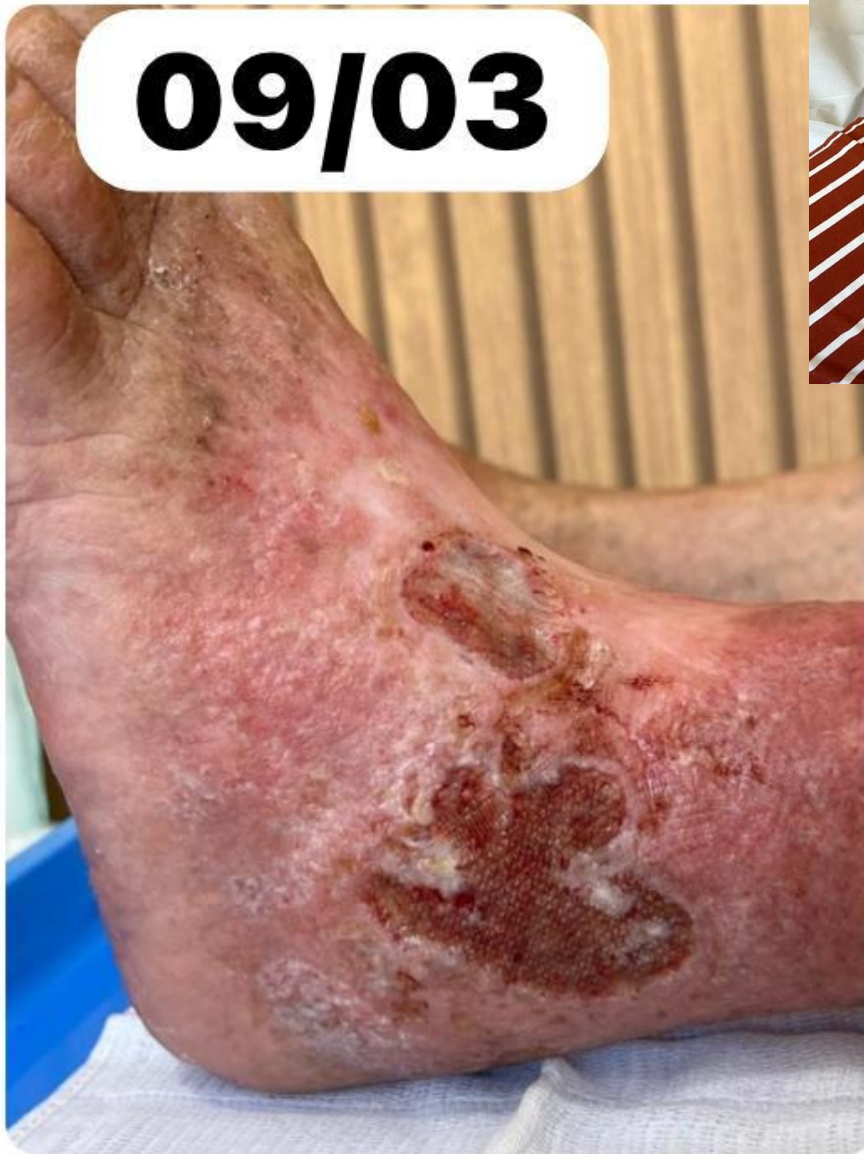Hash (Validador): NjATOMIQ1x8DByeqfJN3kncEY1aM1vltL0T4AJ+G=



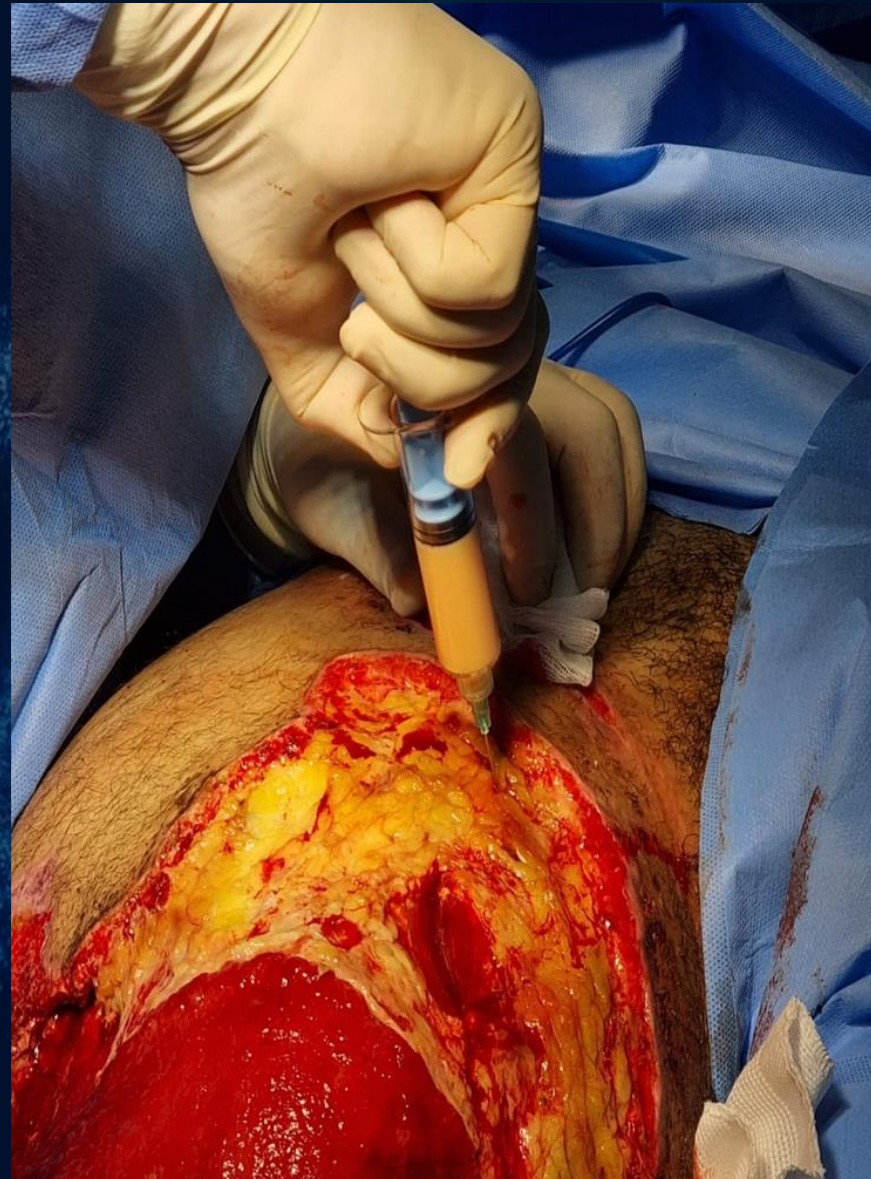
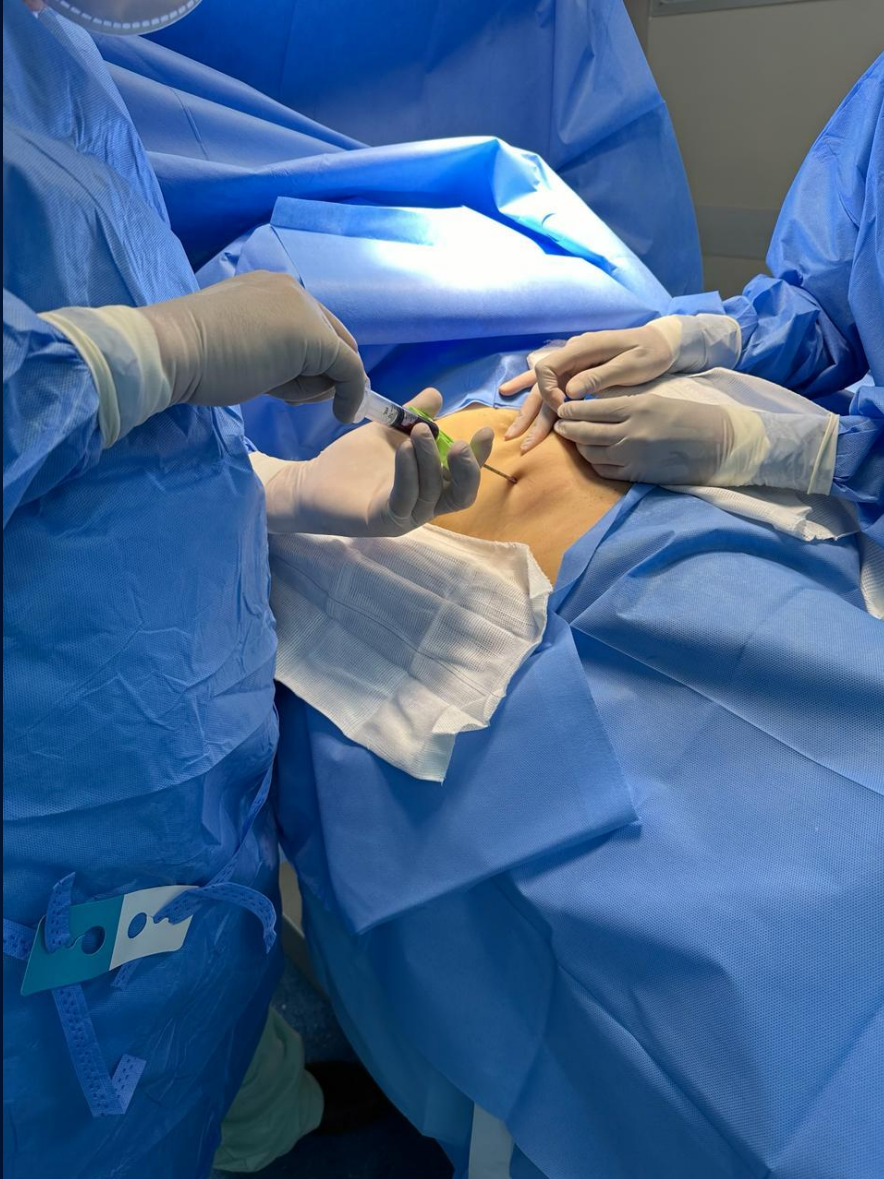06/03



09/03



Bone Marrow Aspirate in complex wounds - Diabetic Foot and severe trauma





Review

Trauma and Stem Cells: Biology and Potential Therapeutic Implications

Kabilan Thurairajah ^{1,2}, Matthew L. Broadhead ^{1,2} and Zsolt J. Balogh ^{1,2,*}

¹ School of Medicine and Public Health, University of Newcastle, Callaghan, NSW 2308, Australia; thu.kabilan@gmail.com (K.T.); matthewbroadhead@me.com (M.L.B.)

² Department of Traumatology, John Hunter Hospital, New Lambton Heights, NSW 2305, Australia

* Correspondence: zsolt.balogh@hnehealth.nsw.gov.au

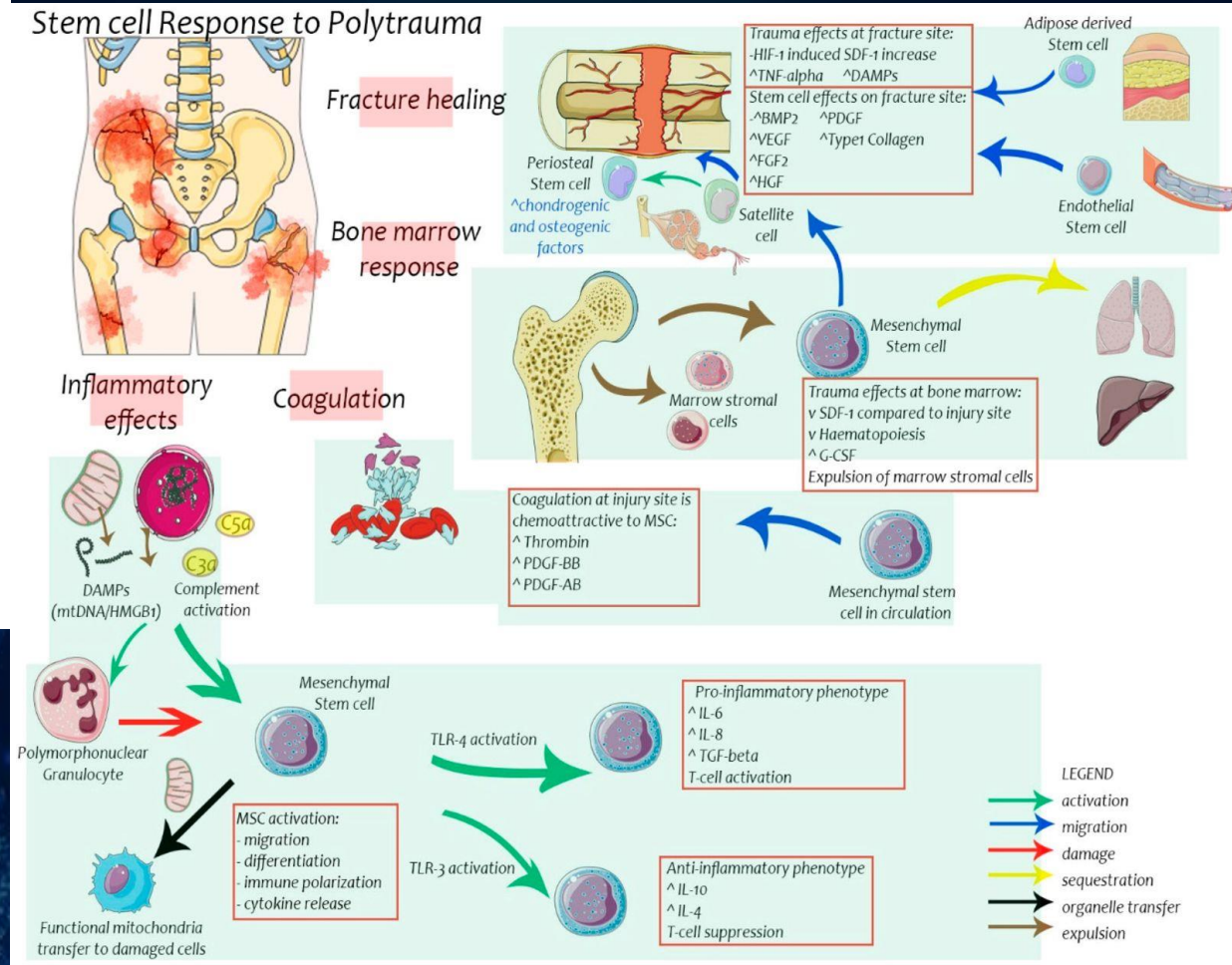
Academic Editor: Cory J. Xian

Received: 17 January 2017; Accepted: 2 March 2017; Published: 7 March 2017

Abstract: Trauma may cause irreversible tissue damage and loss of function despite current best practice. Healing is dependent both on the nature of the injury and the intrinsic biological capacity of those tissues for healing. Preclinical research has highlighted stem cell therapy as a potential avenue for improving outcomes for injuries with poor healing capacity. Additionally, trauma activates the immune system and alters stem cell behaviour. This paper reviews the current literature on stem cells and its relevance to trauma care. Emphasis is placed on understanding how stem cells respond to trauma and pertinent mechanisms that can be utilised to promote tissue healing. Research involving notable difficulties in trauma care such as fracture non-union, cartilage damage and trauma induced inflammation is discussed further.

Keywords: trauma; stem cells; inflammation; DAMP; healing

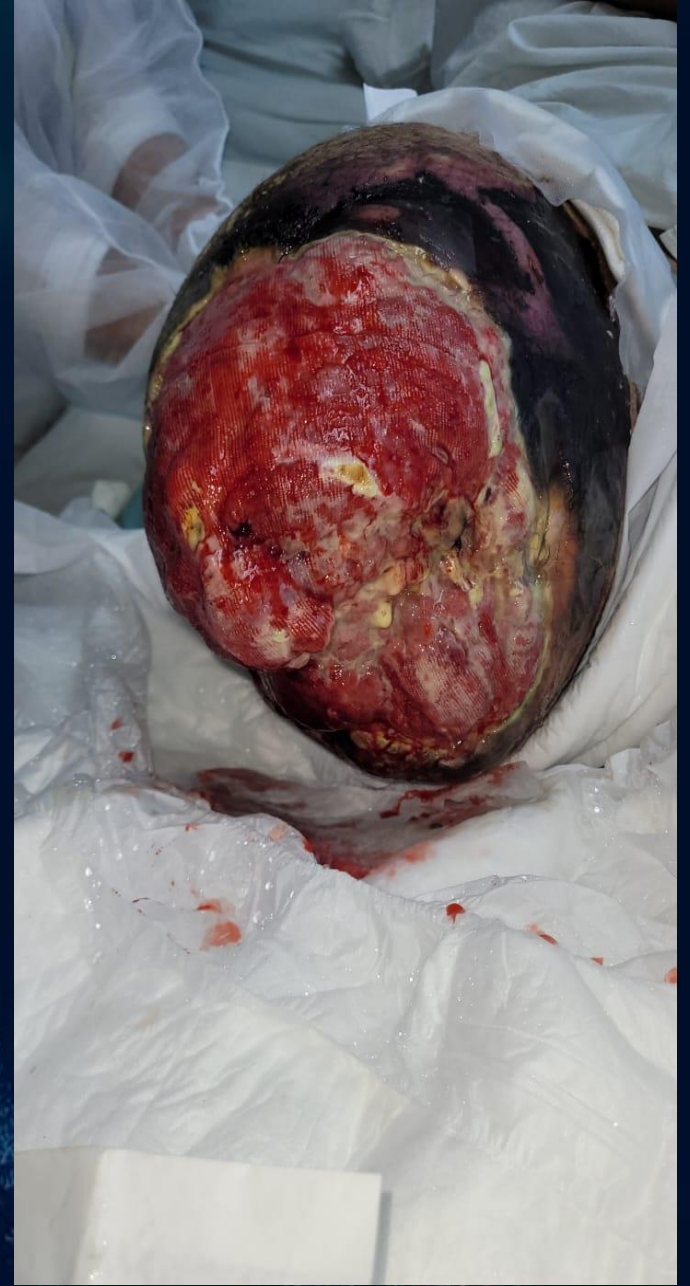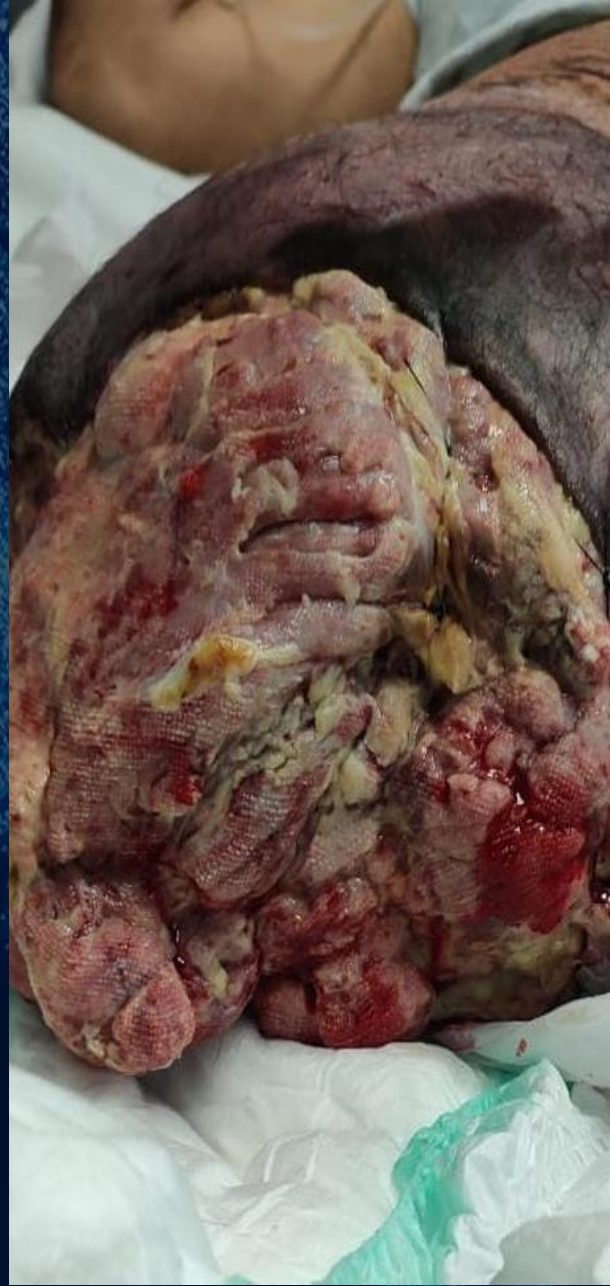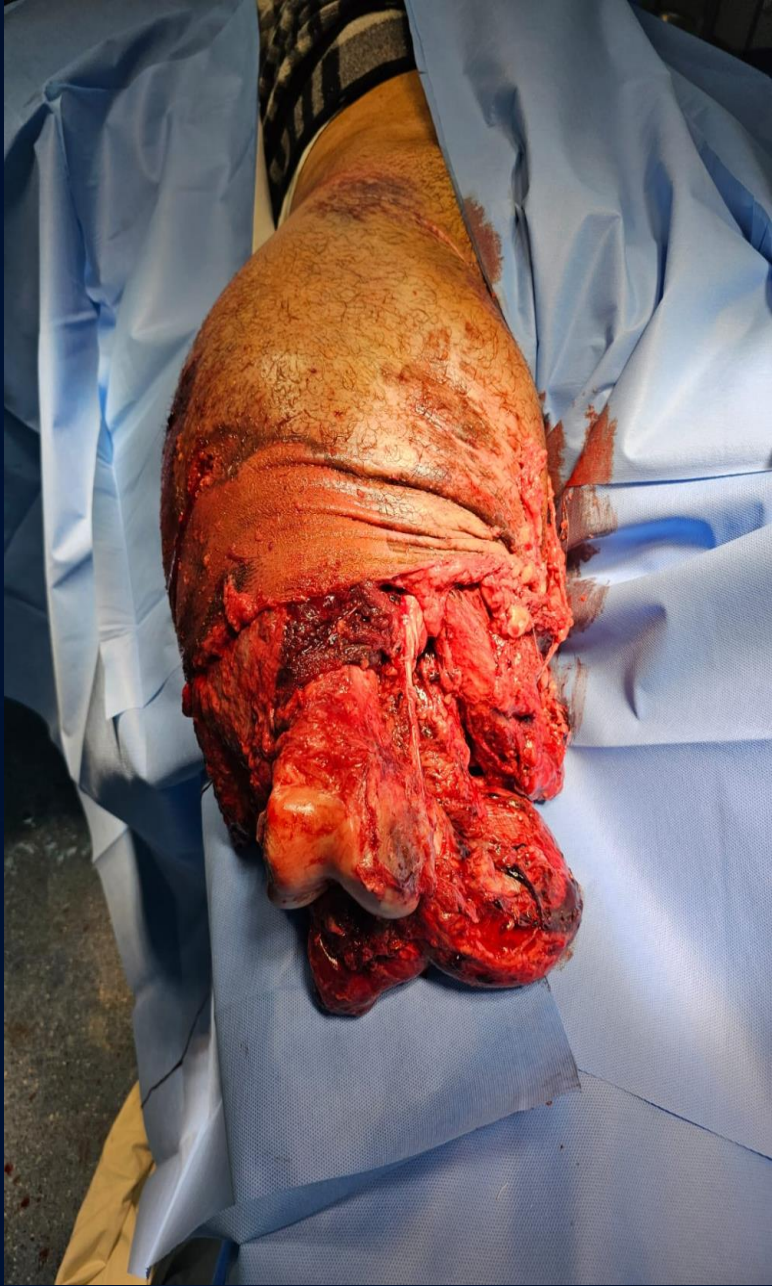Stem cell Response to Polytrauma

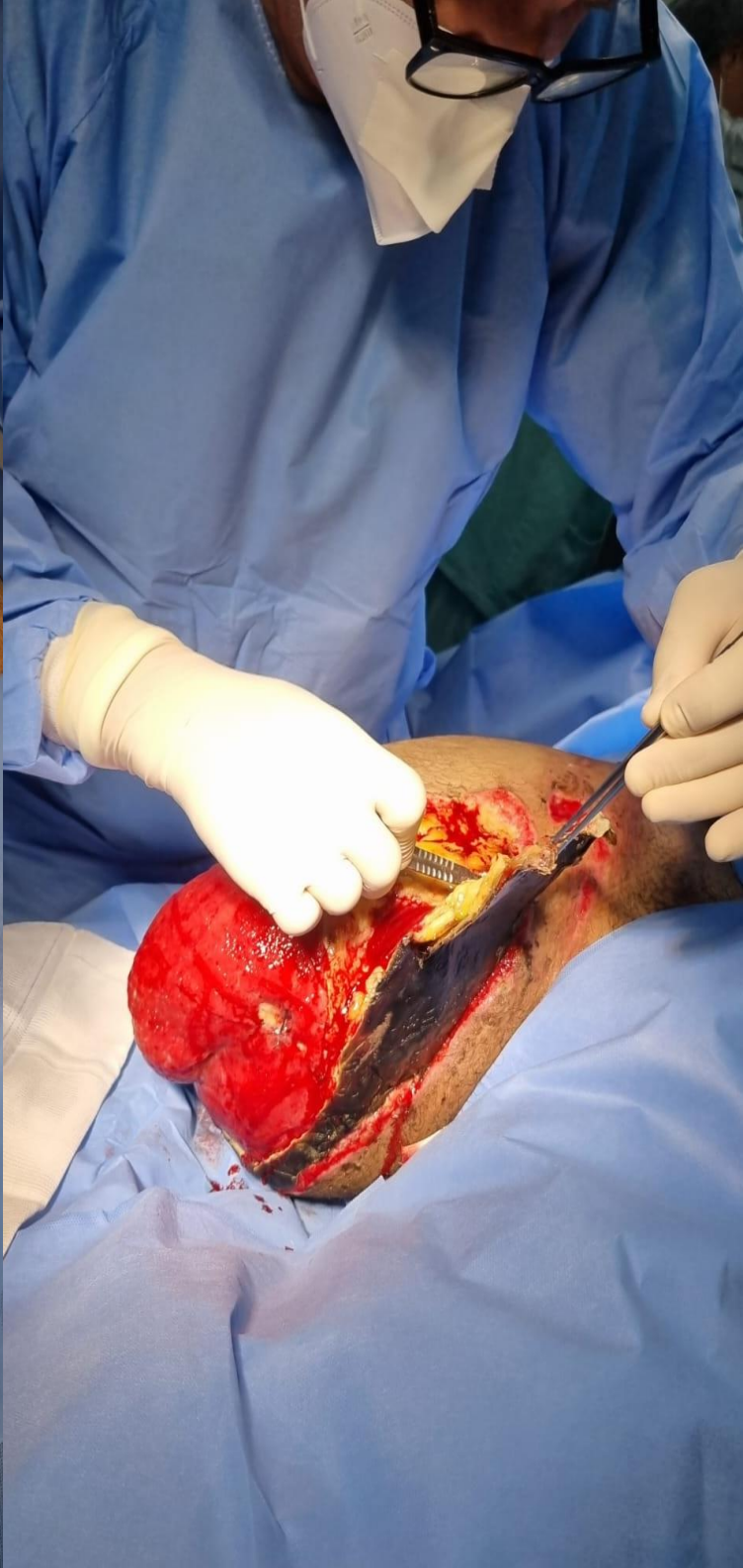
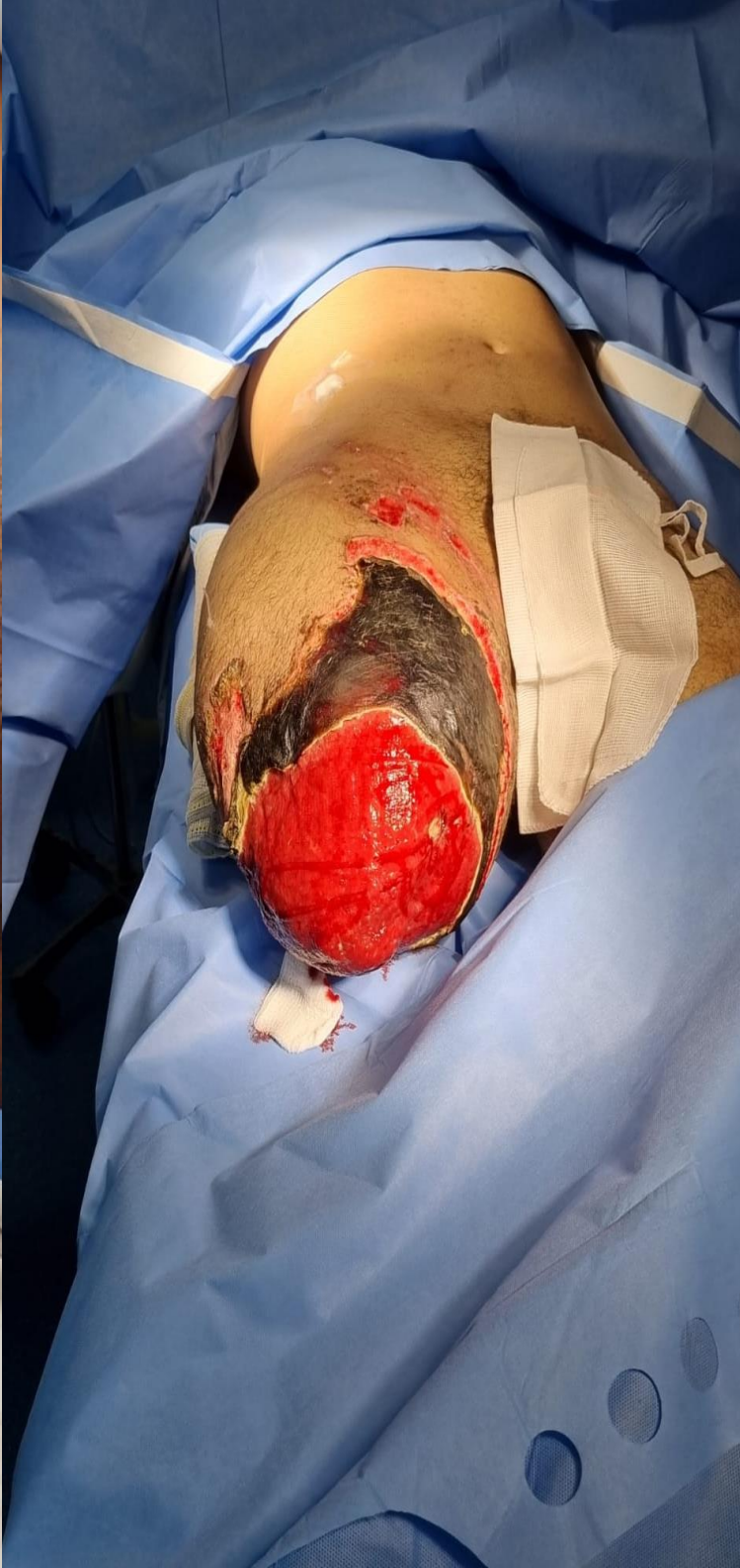
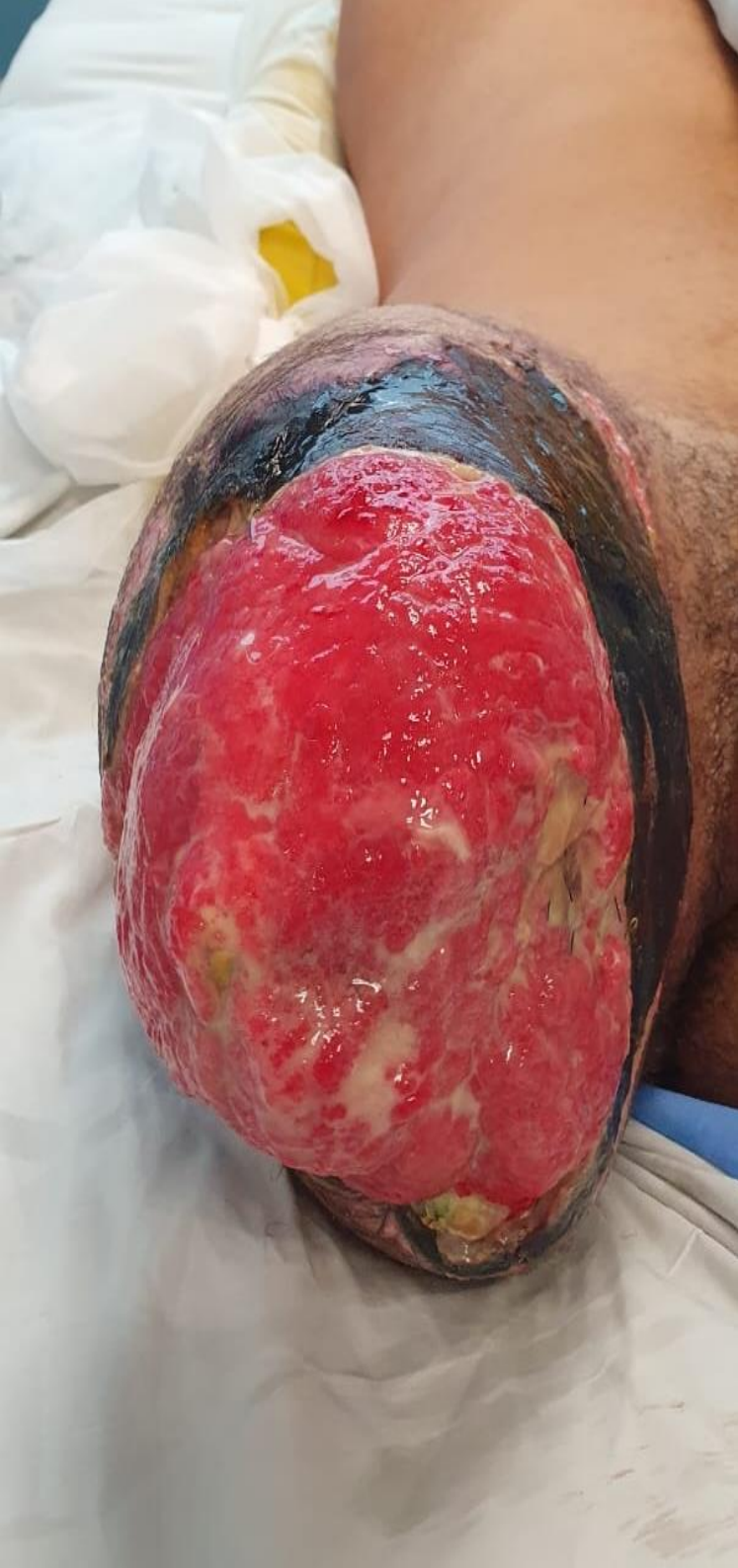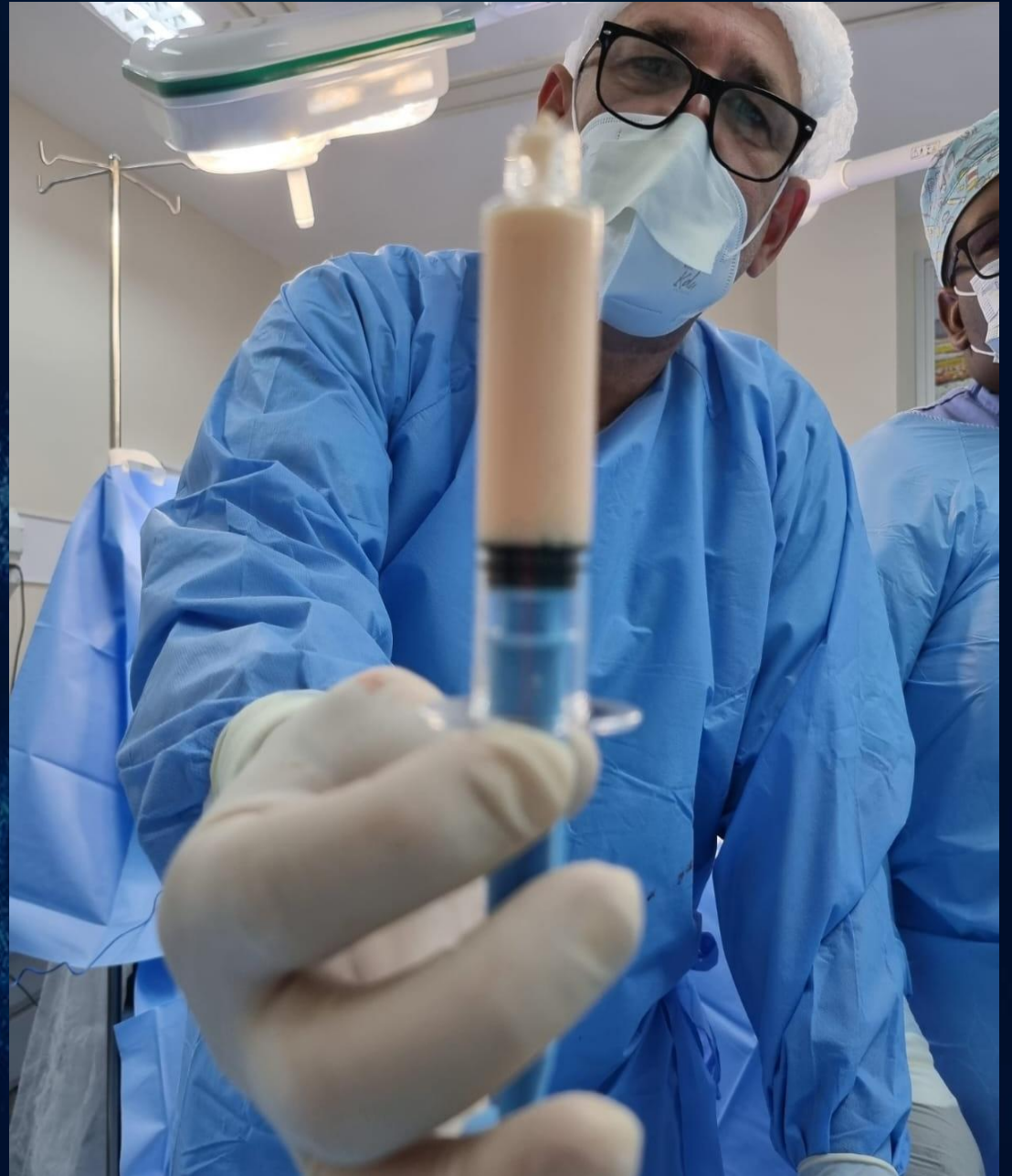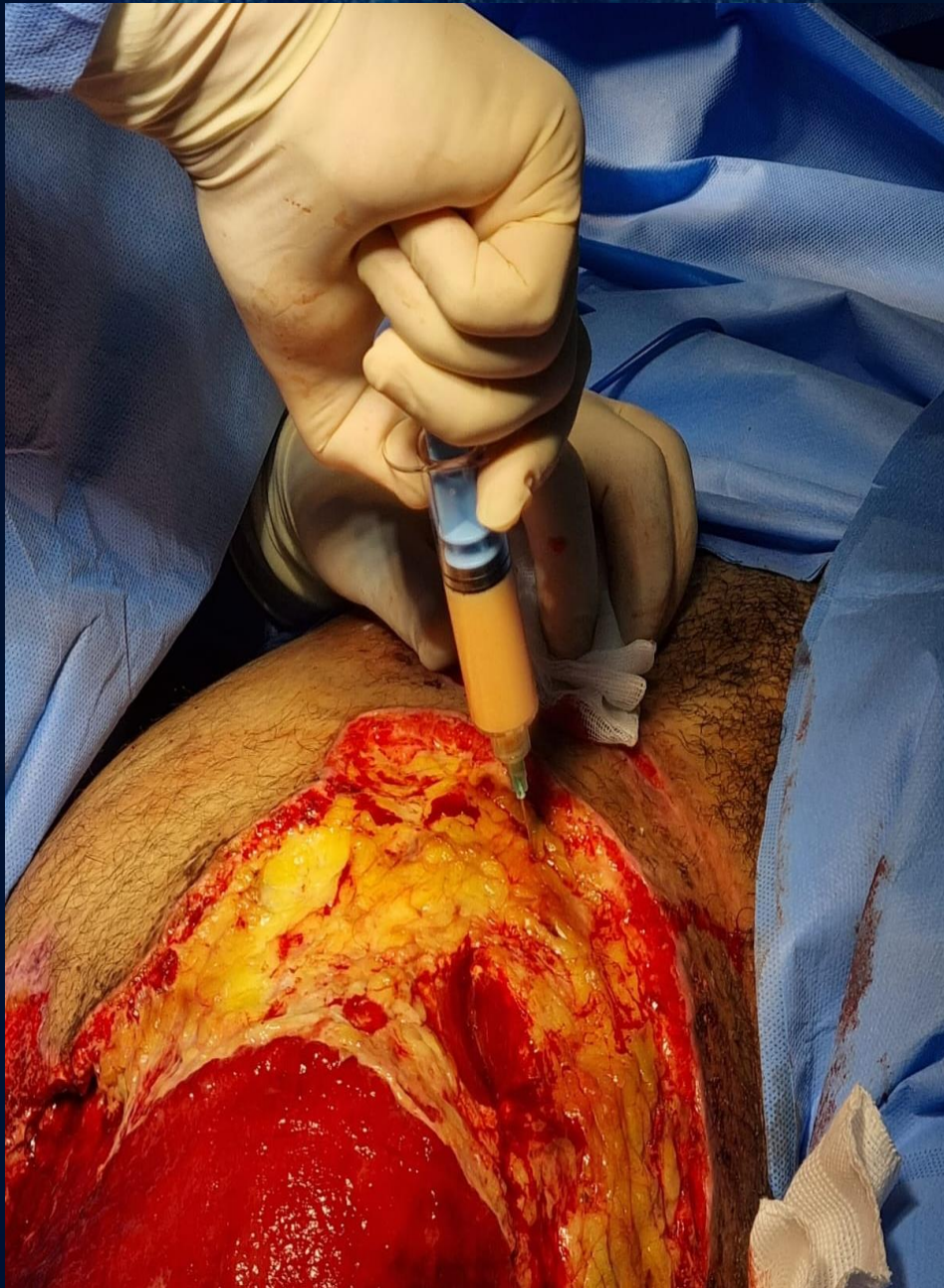
Internacional J. Mol. Ciência. 2017 , 18 (3), 577;
<https://doi.org/10.3390/ijms18030577>

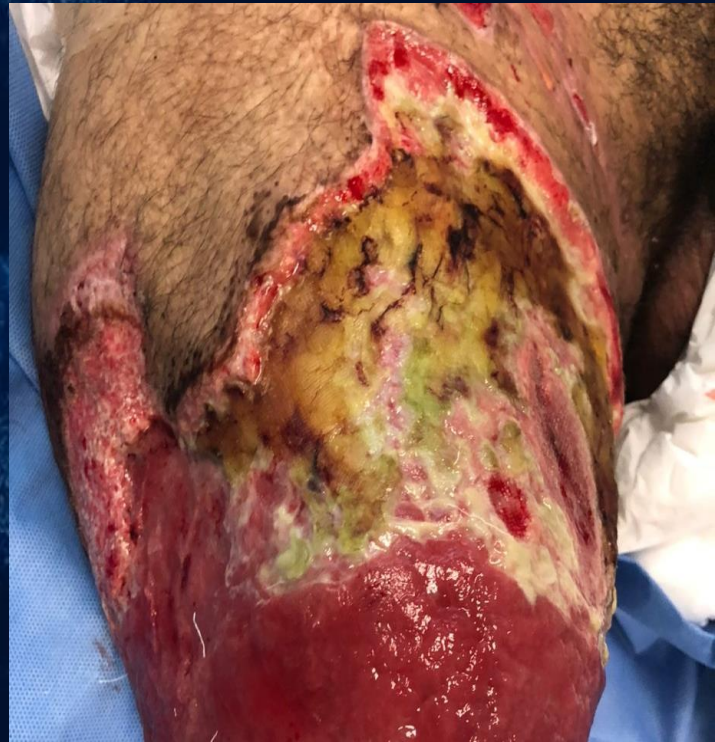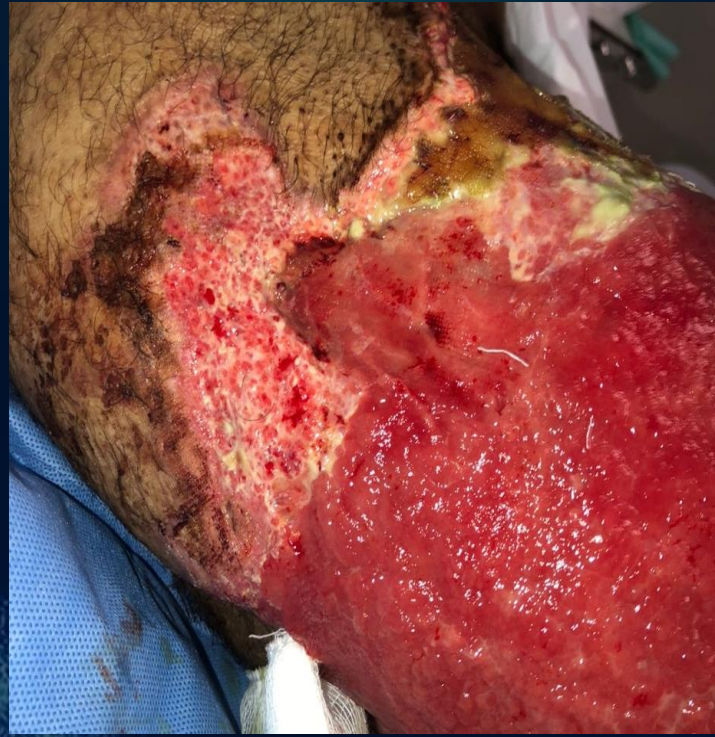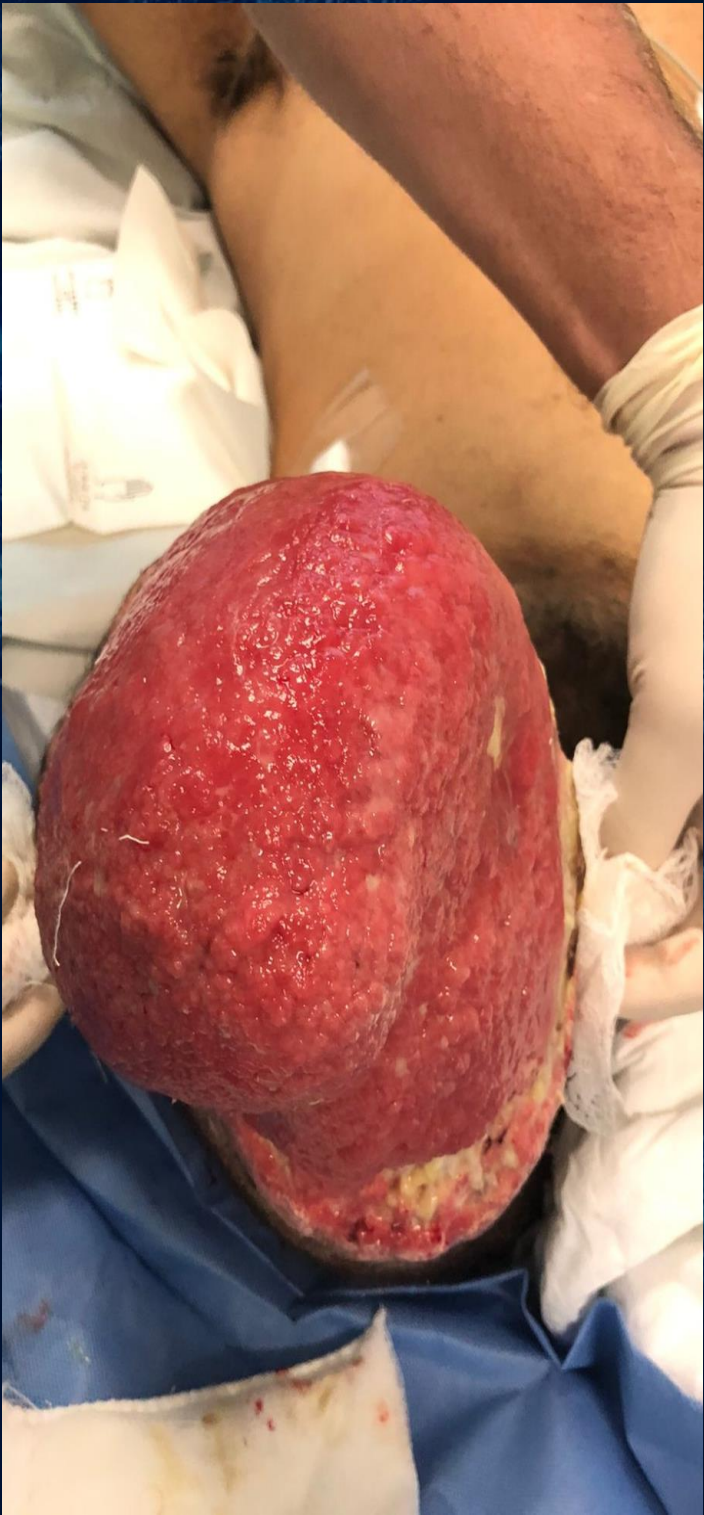Clinical Case 55 - C55

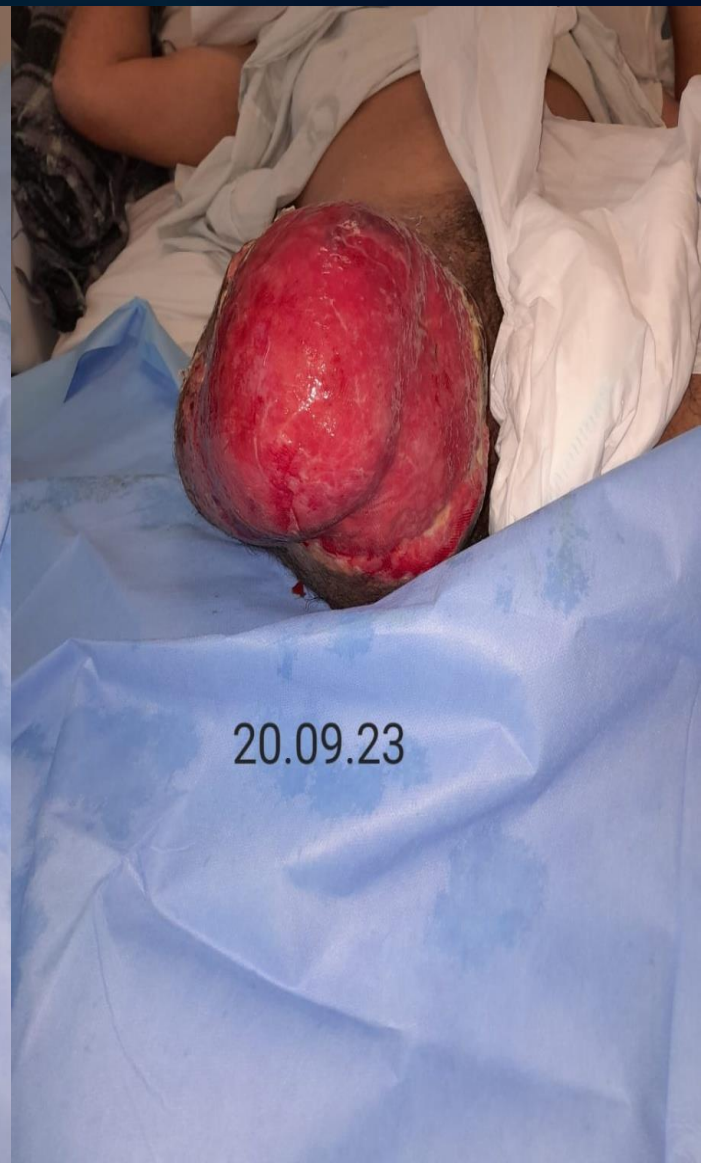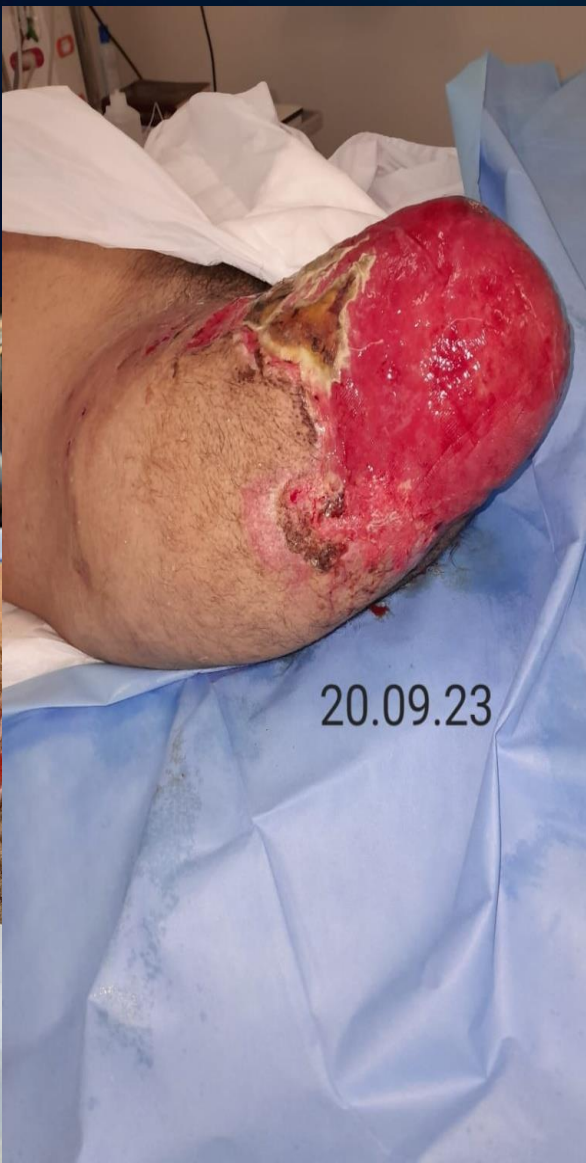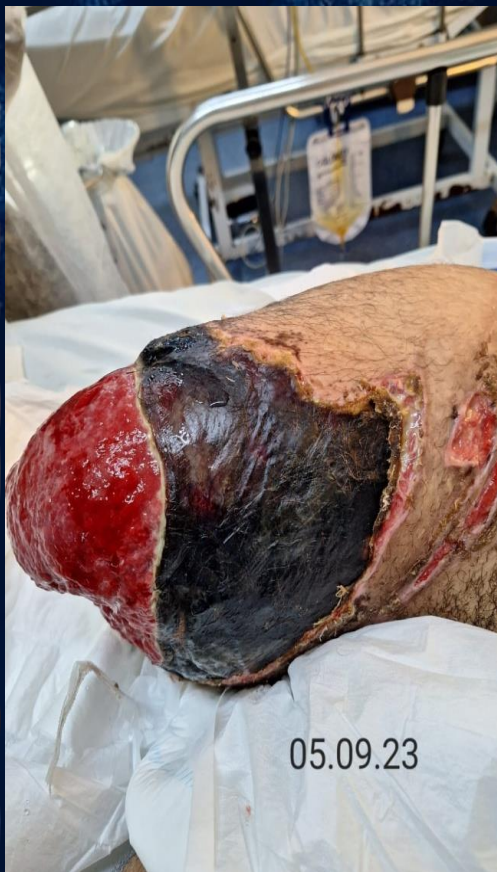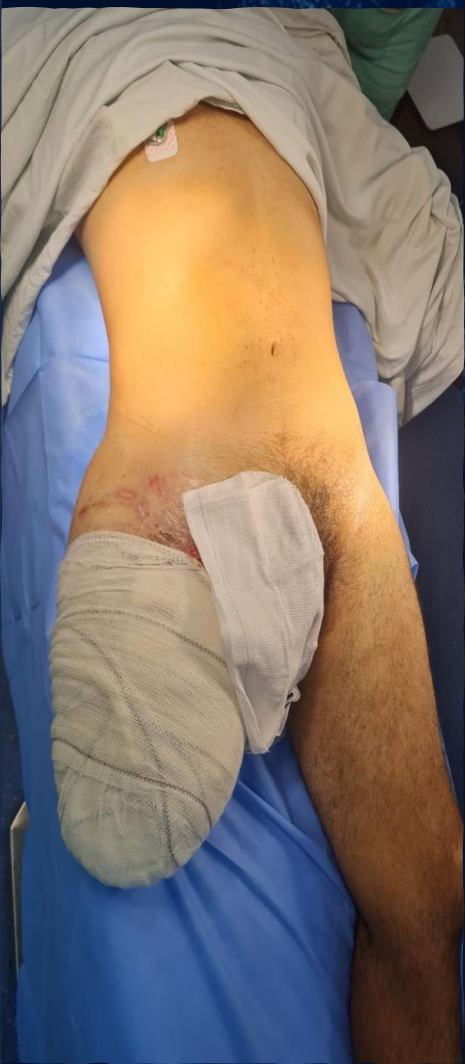- 26-year-old Patient
- Polytrauma – motorcycle-car collision
- Severe injury to the right lower limb – crushing of the foot and leg
- Fracture with loss of substance and traumatic injury to the femoral artery
- Unsuccessful attempt at thigh revascularization
- After 1 week, hip disarticulation was recommended
- Opted for debridement, hyperbaric therapy, regenerative therapy with microfragmented autologous fat - Sefficare

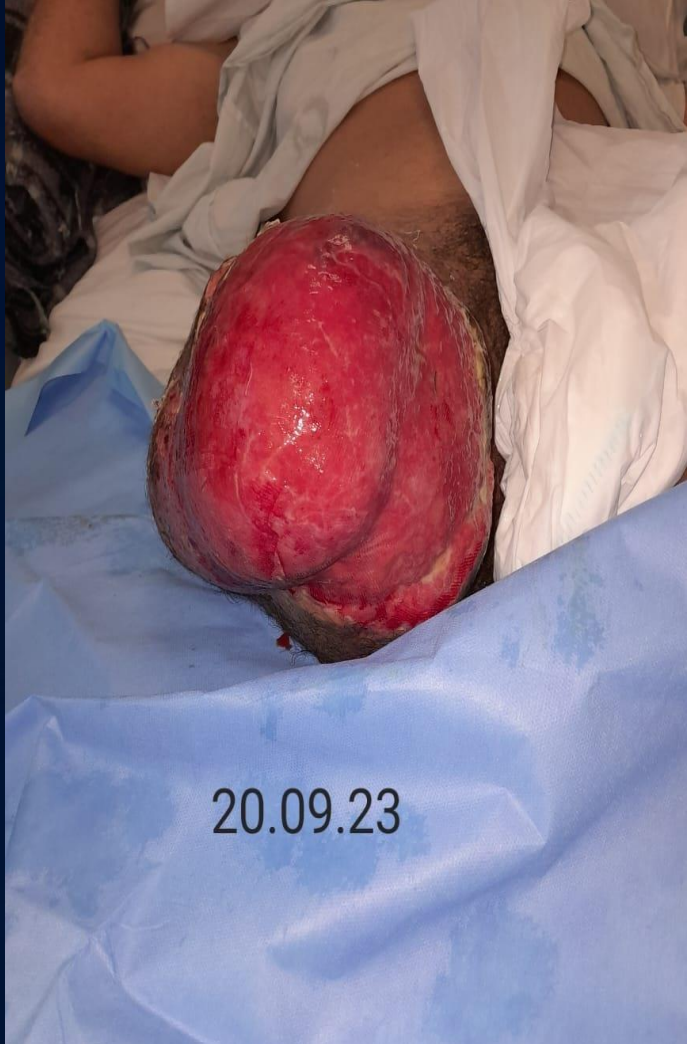




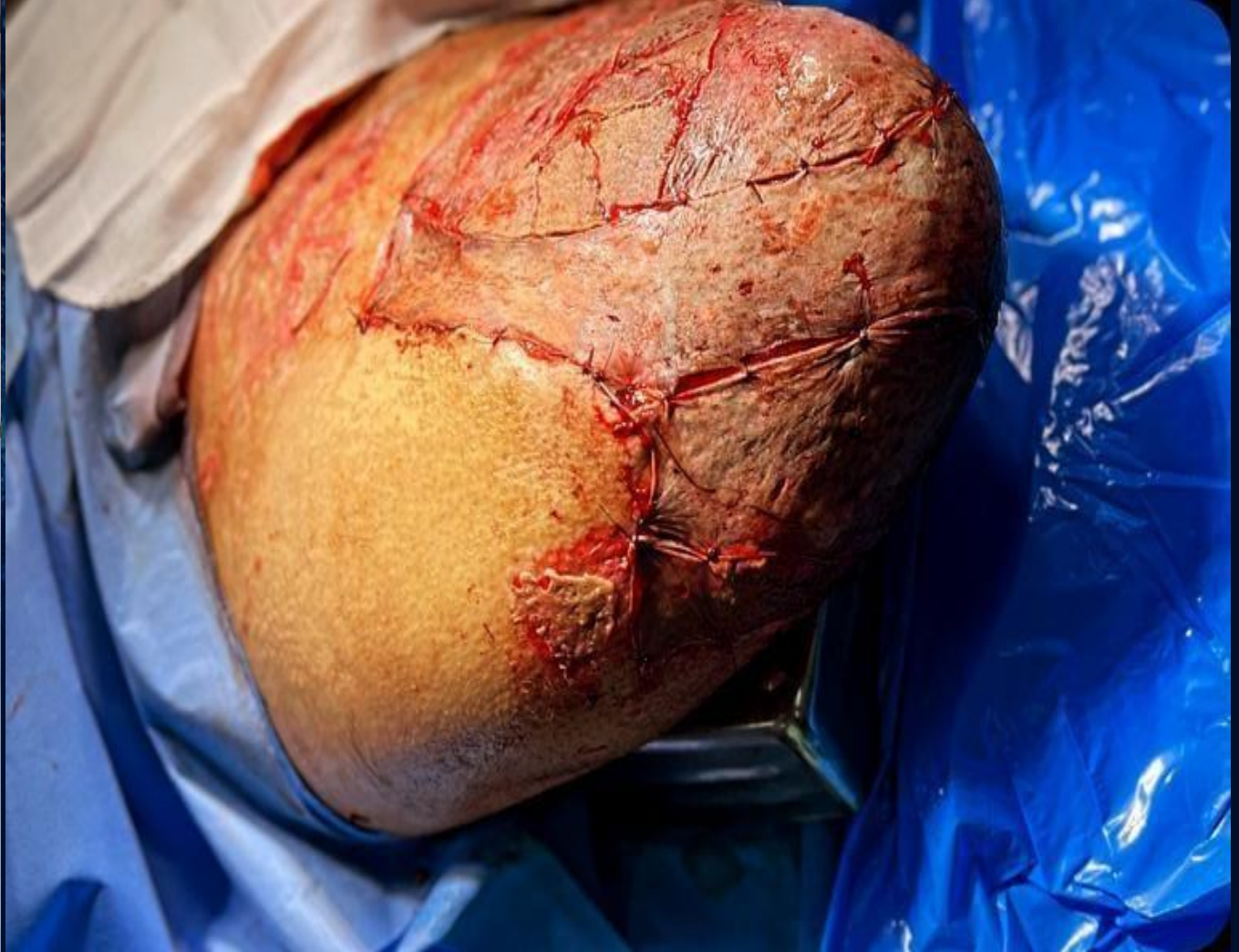


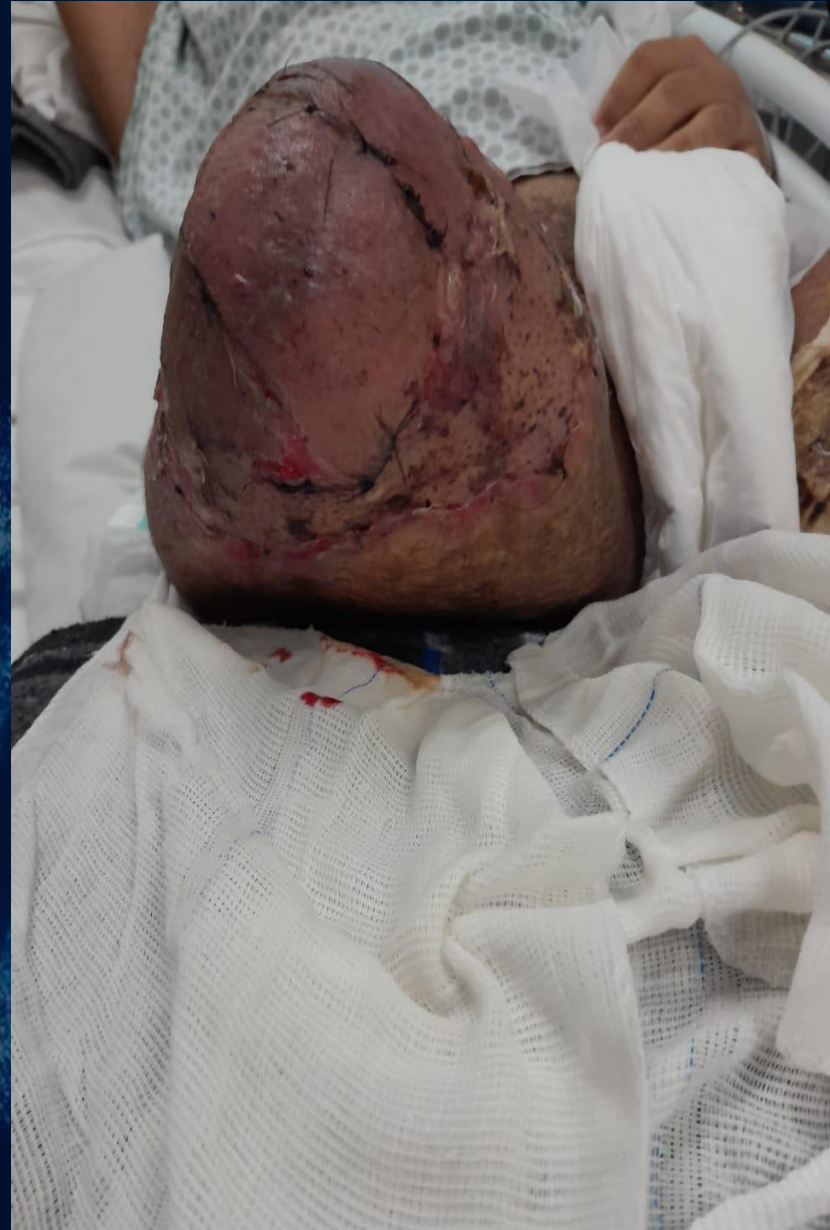
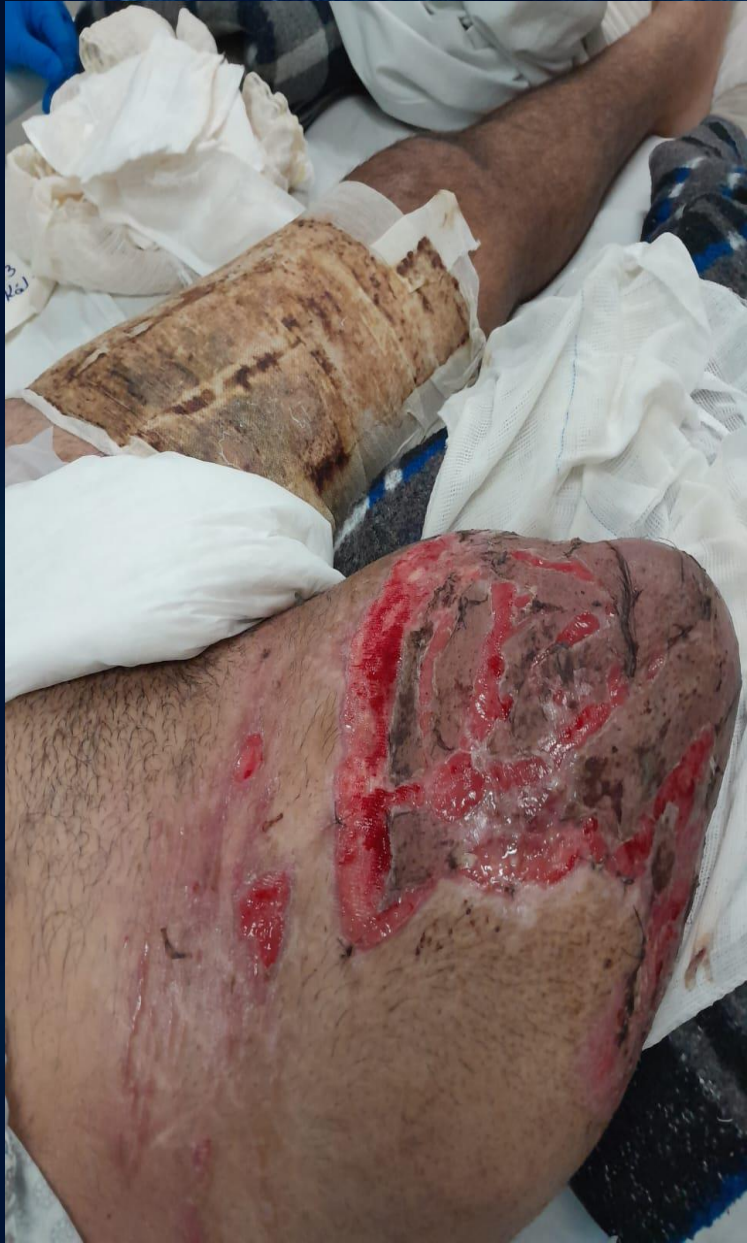

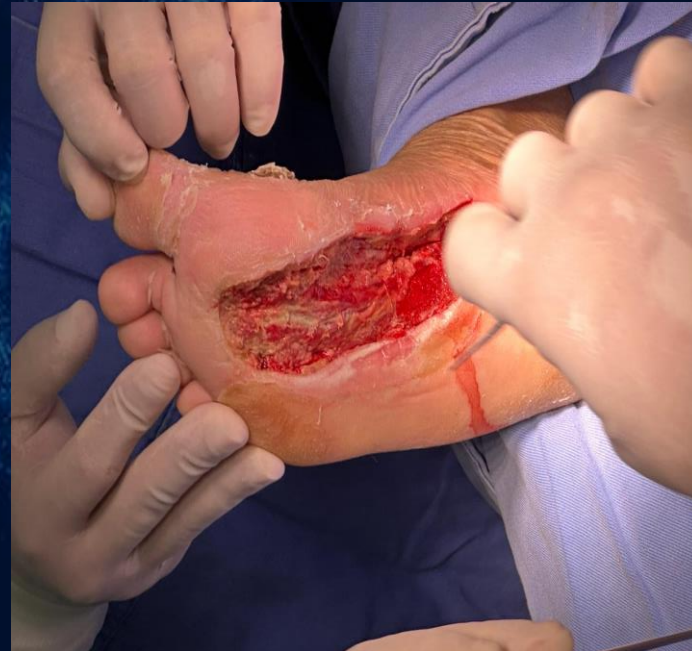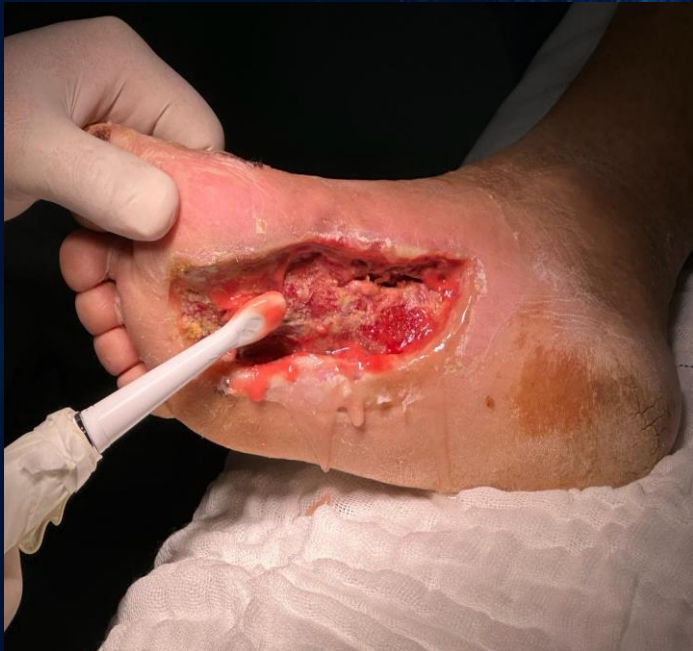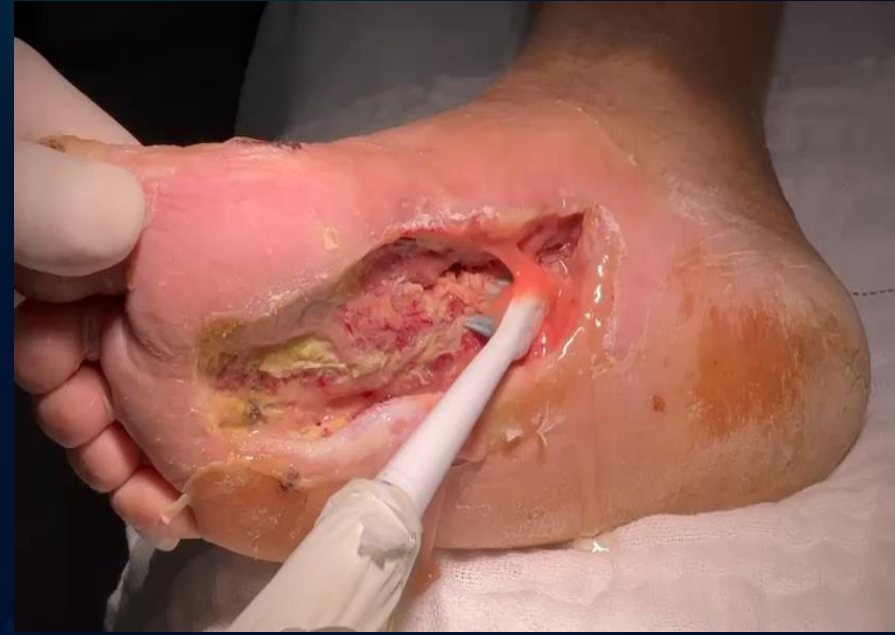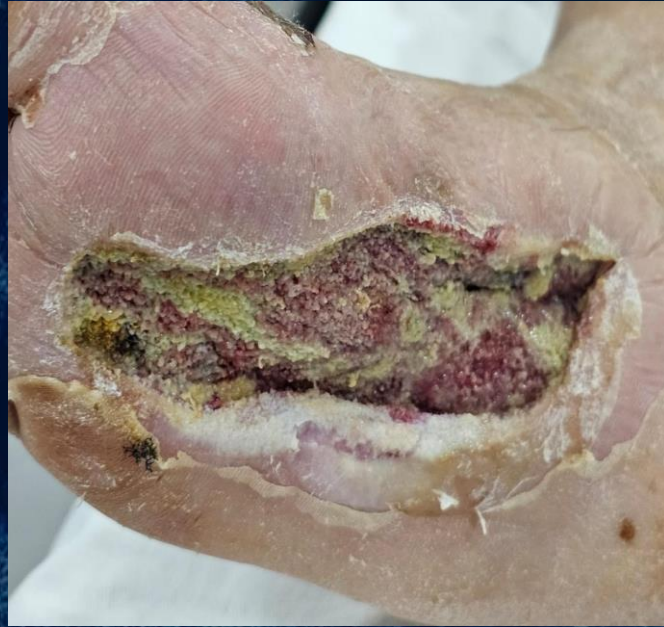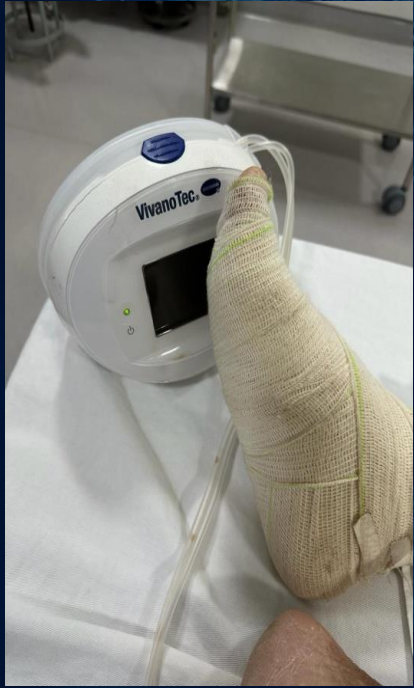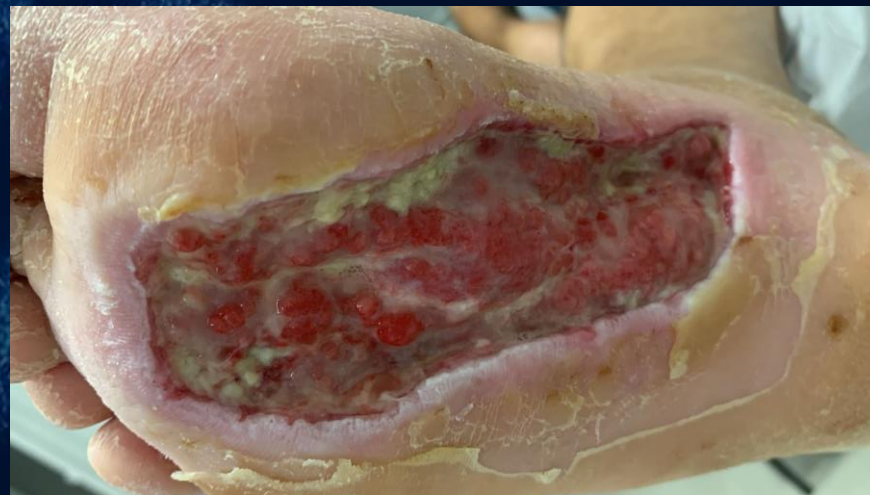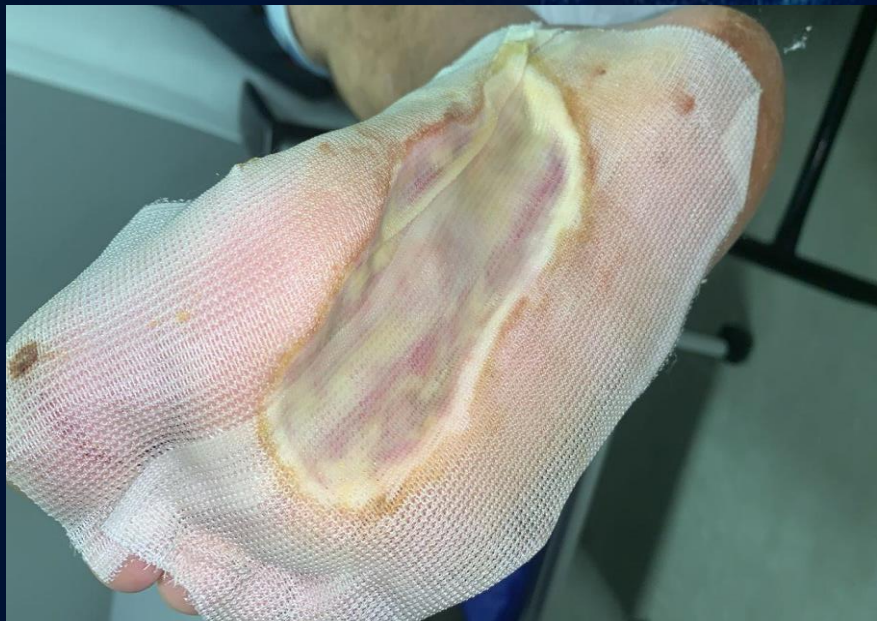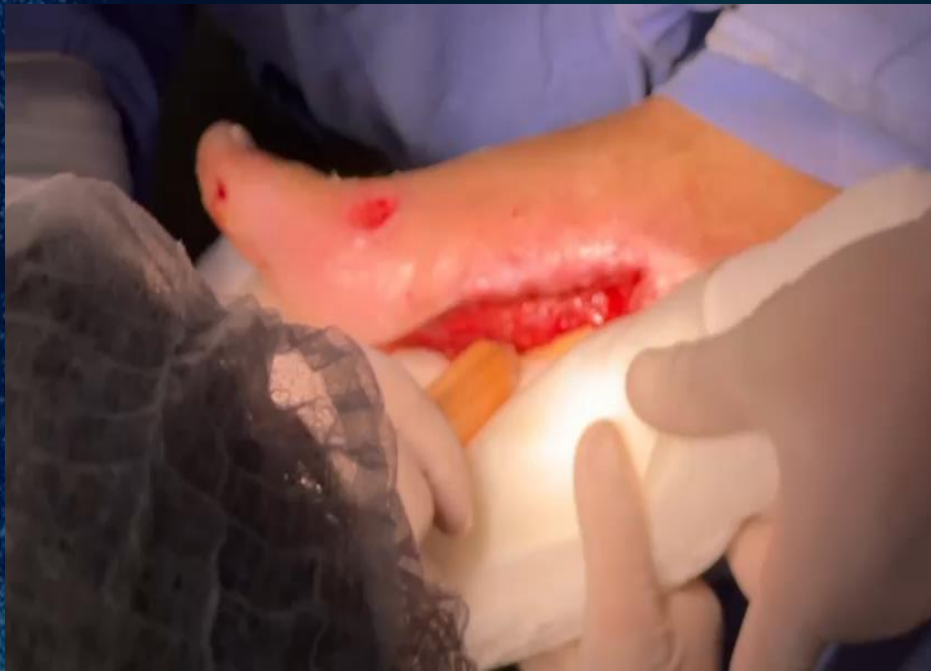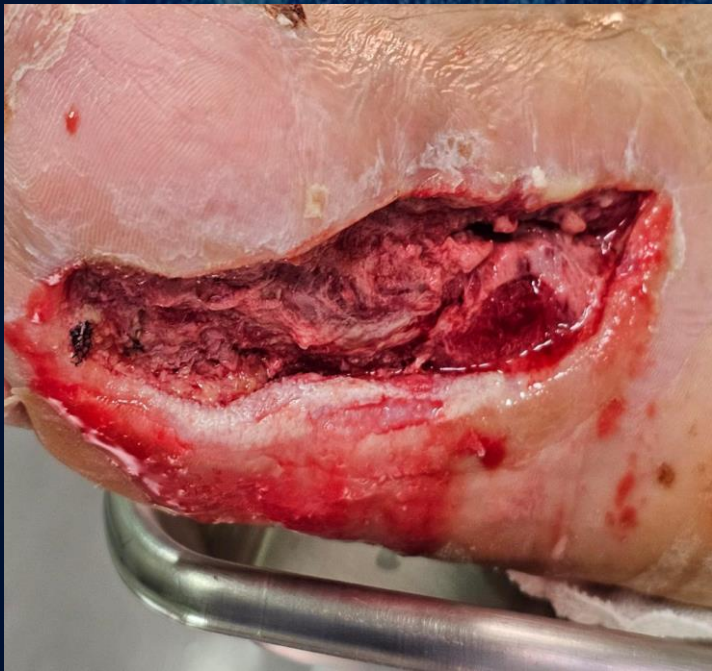


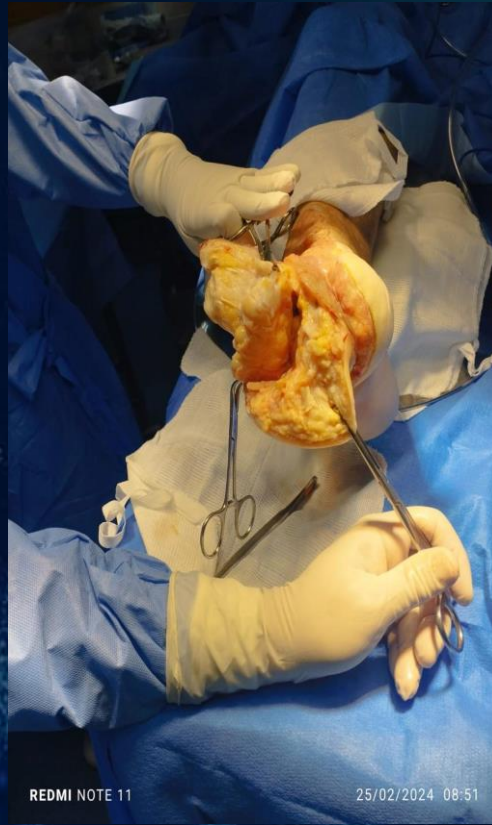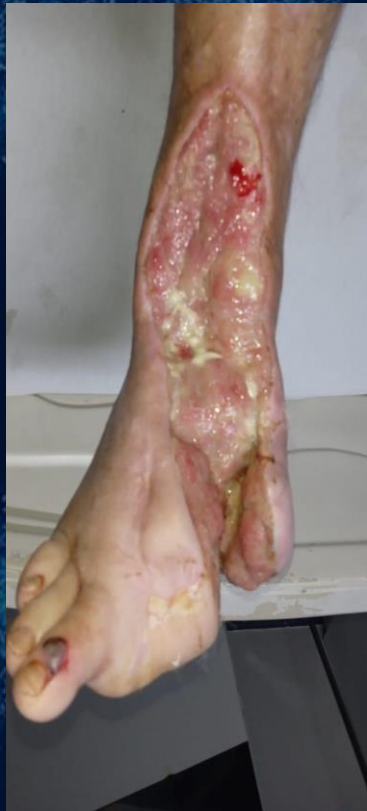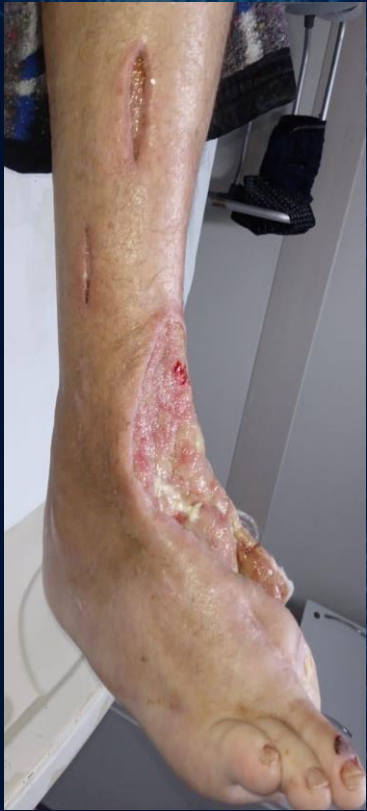20.09.23





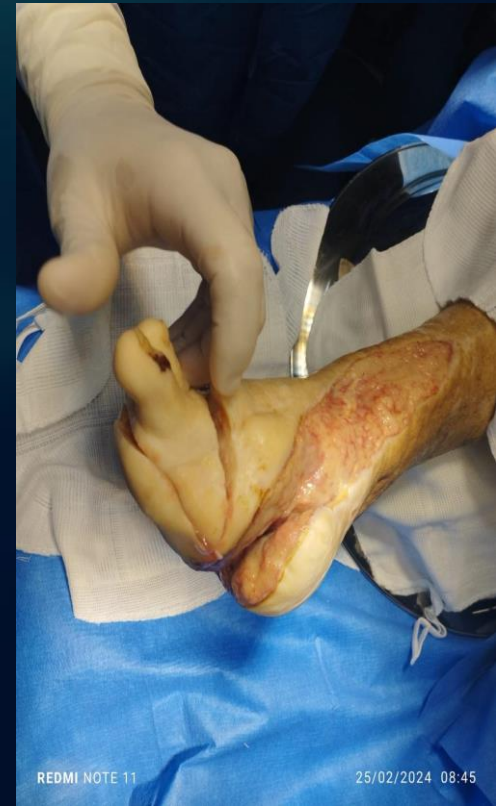





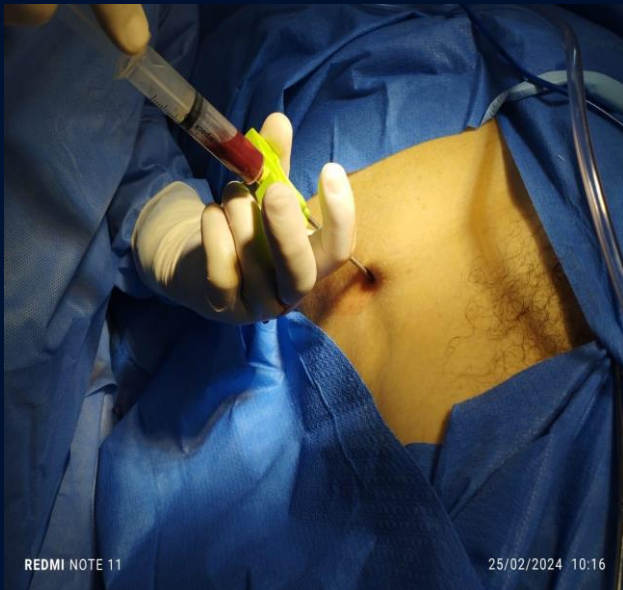REDMI NOTE 11

25/02/2024 08:51



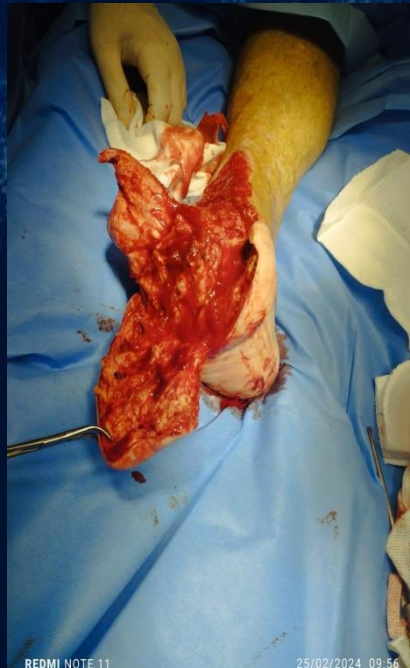REDMI NOTE 11

25/02/2024 08:45



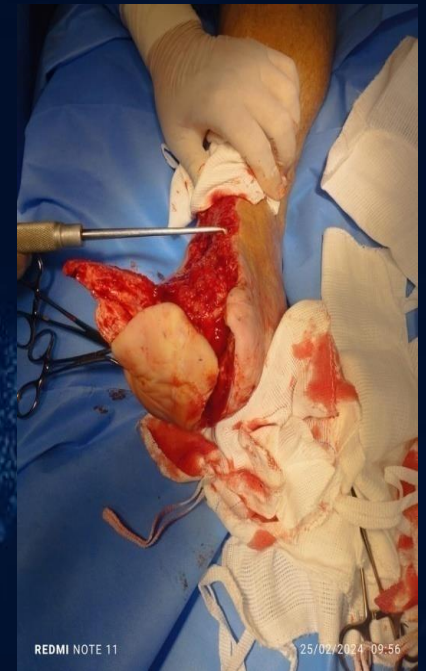REDMI NOTE 11

25/02/2024 10:16



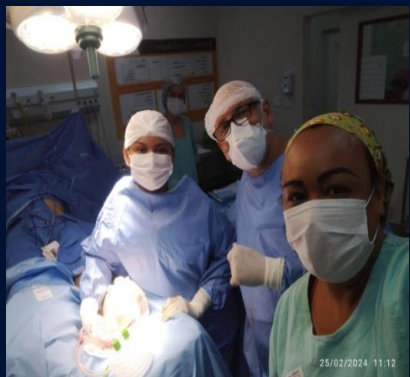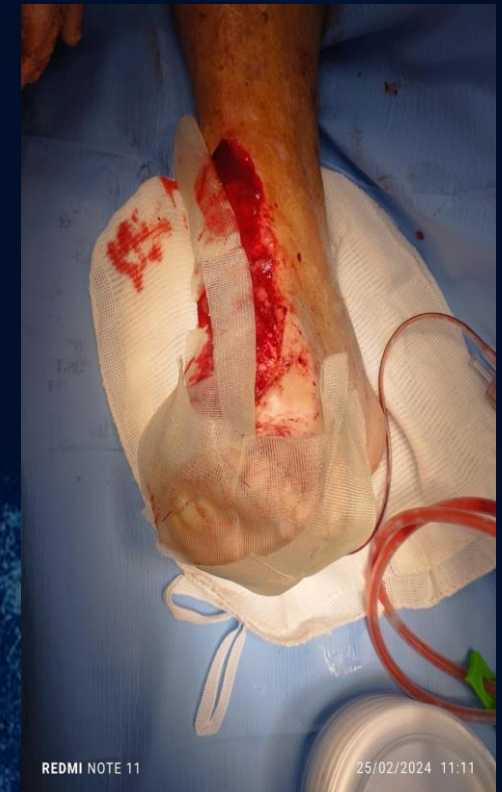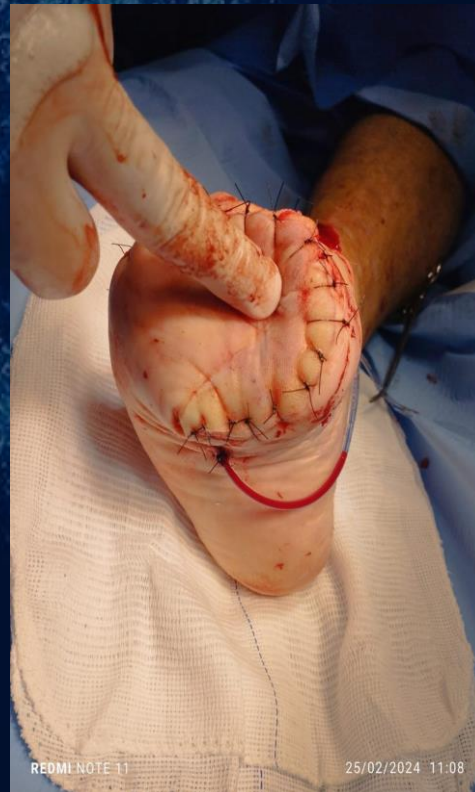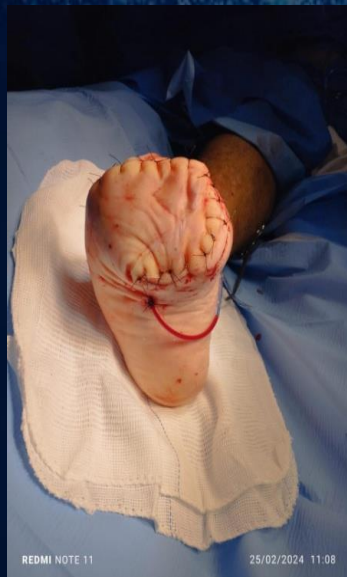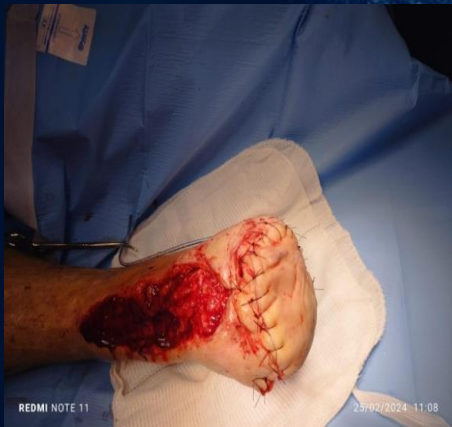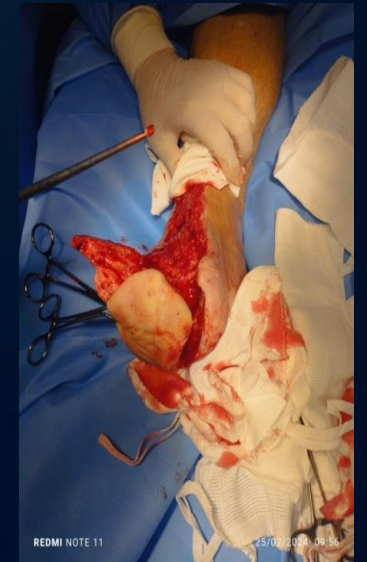
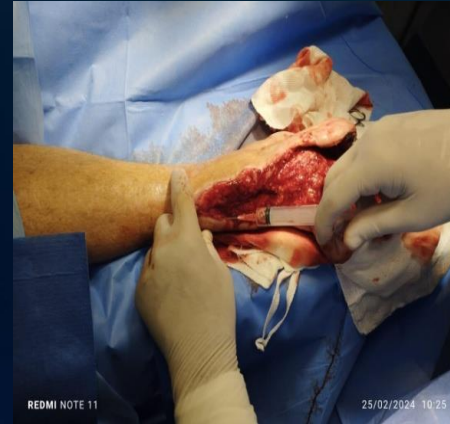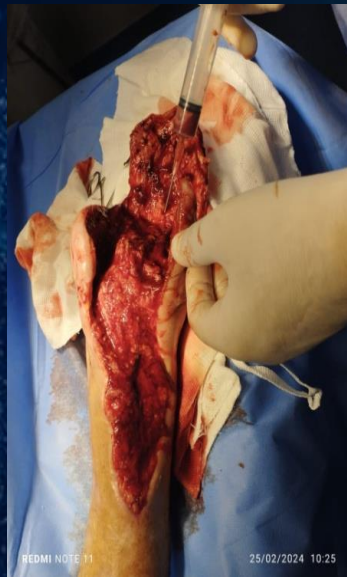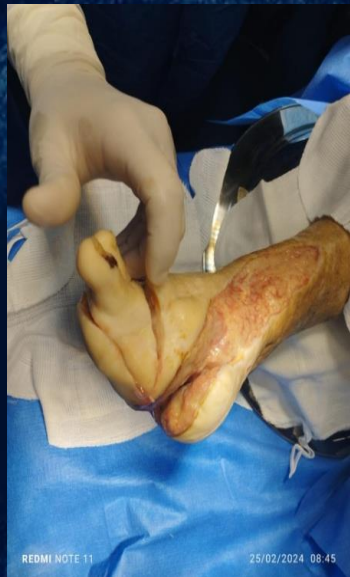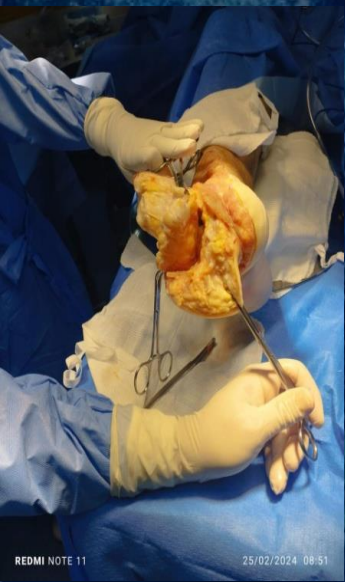REDMI NOTE 11

25/02/2024 09:56



REDMI NOTE 11

25/02/2024 09:56



Severe trauma with crushing of the foot

Vascular Surgery

Doppler

Arteriography

2 weeks delineating the necrotic area and reducing inflammatory/infectious activity

Hyperbaric Oxygen Therapy for 10 days

Midfoot resection

Debridement of the devitalized area - Physiotherapy

Bone Marrow Aspiration (BMA)

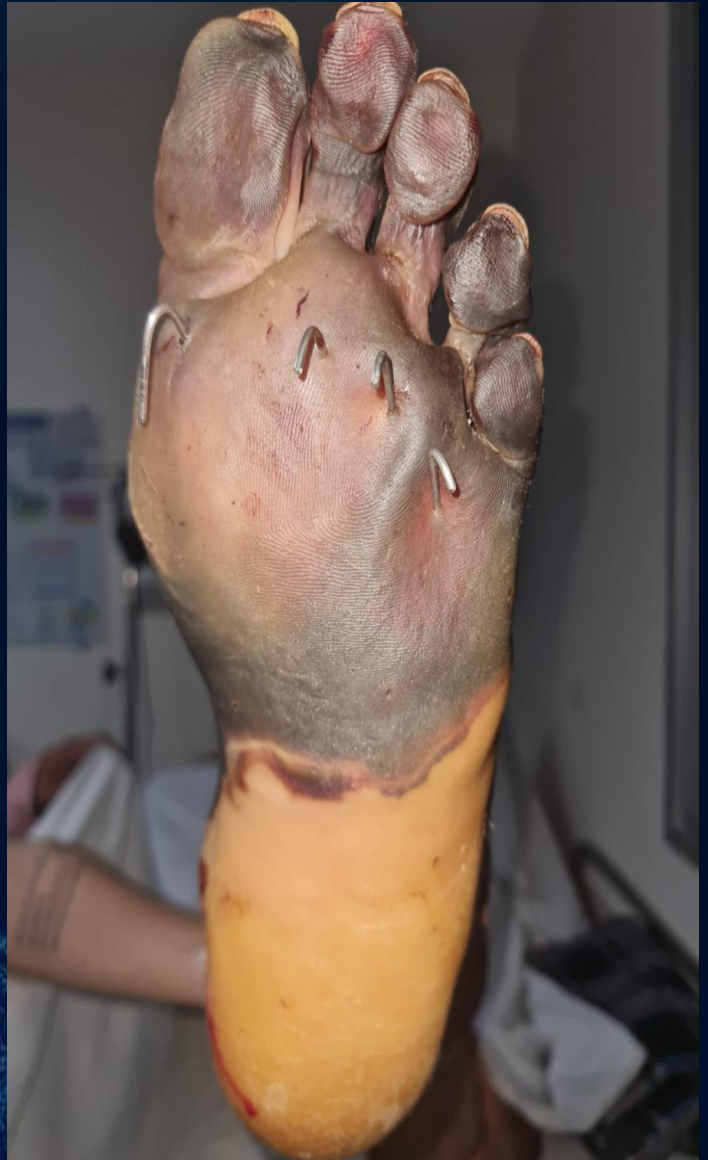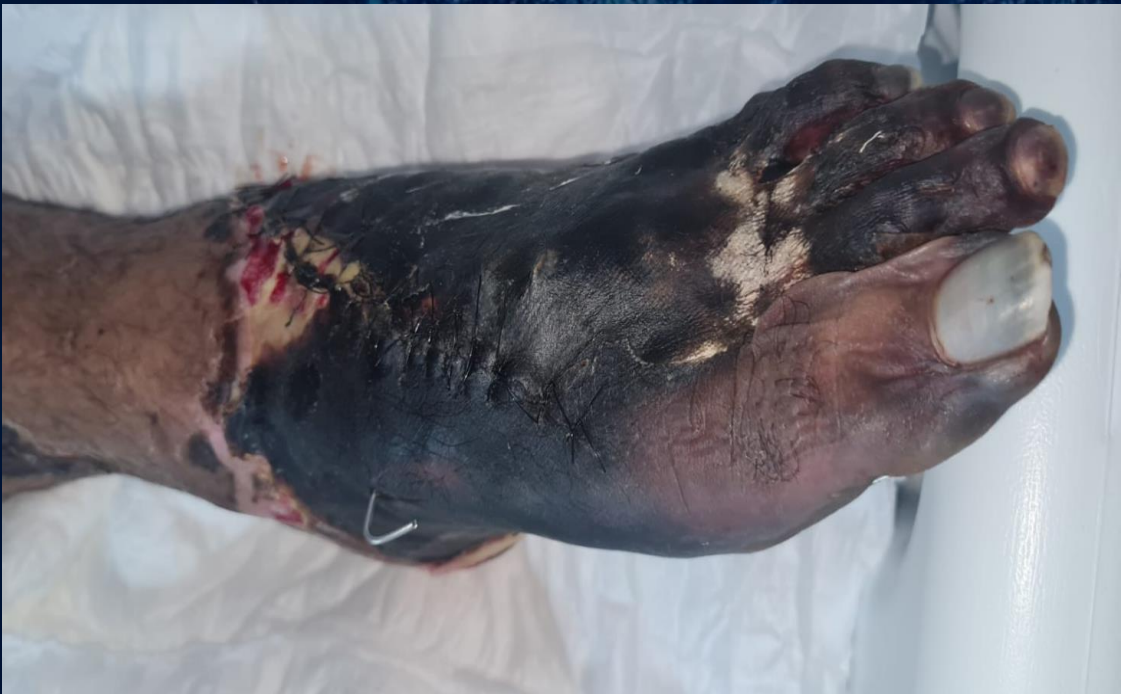7 days of Hyperbaric Oxygen Therapy

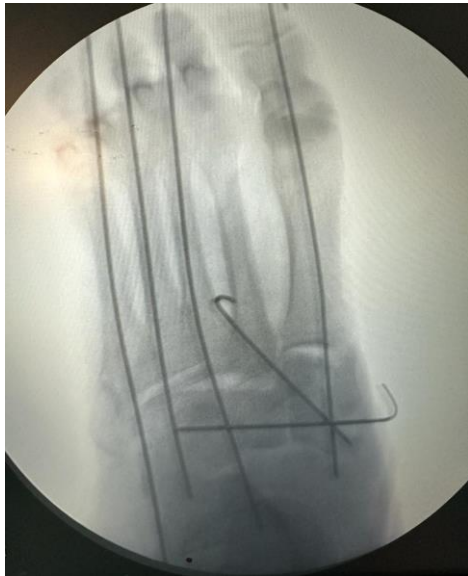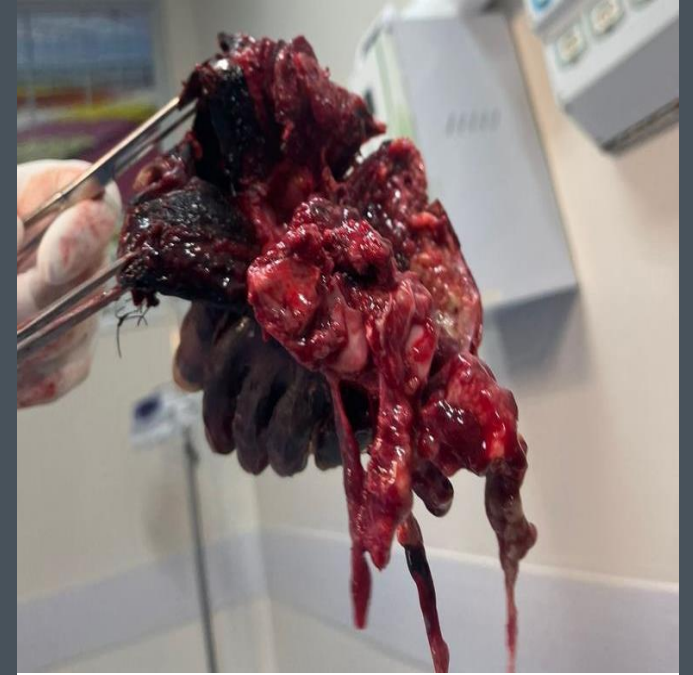
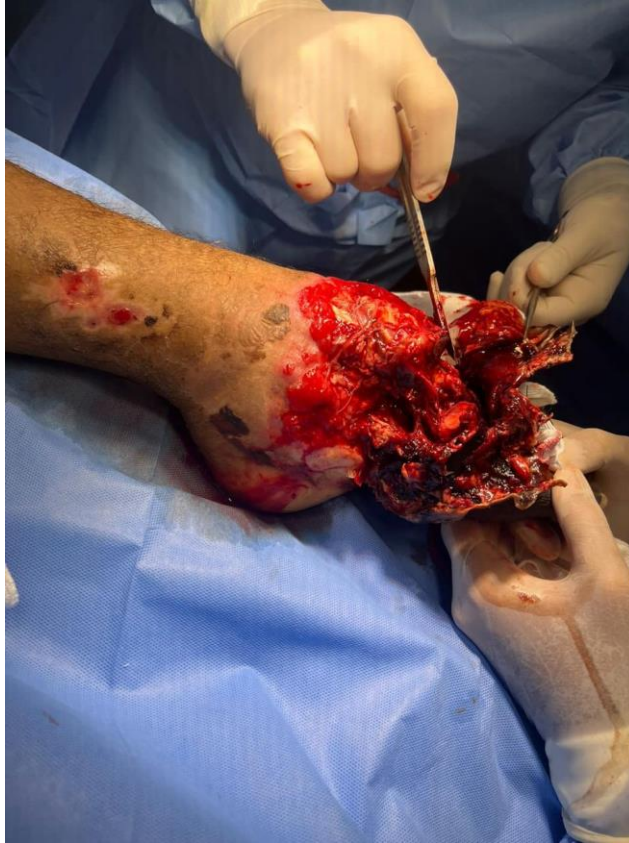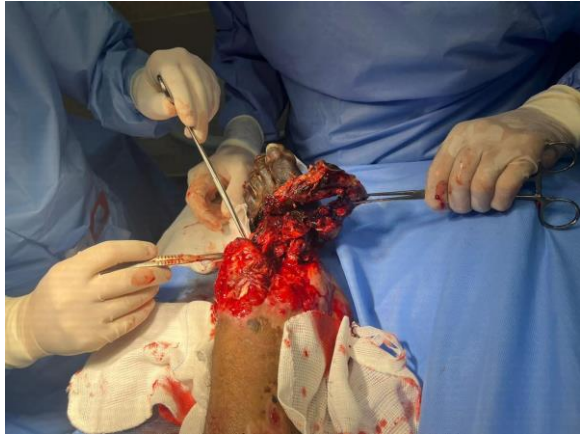Subsequent debridement

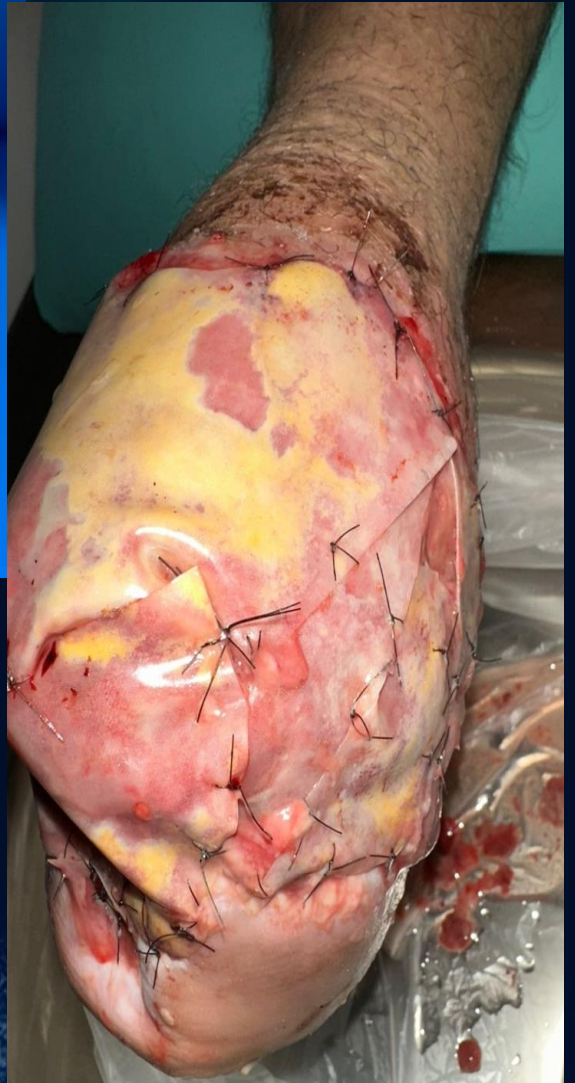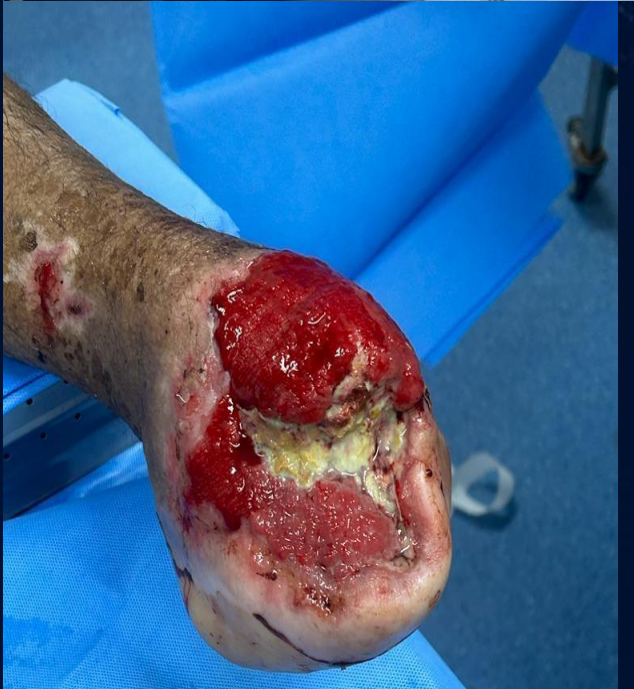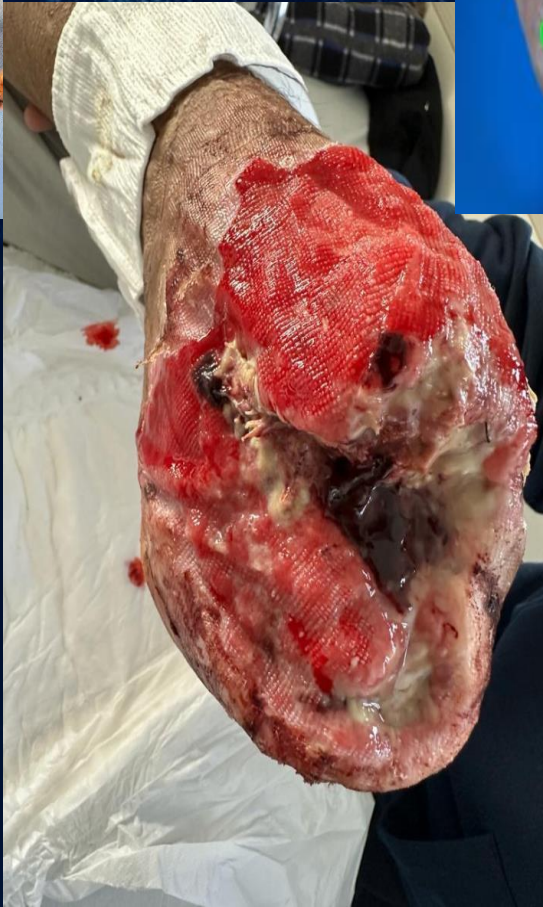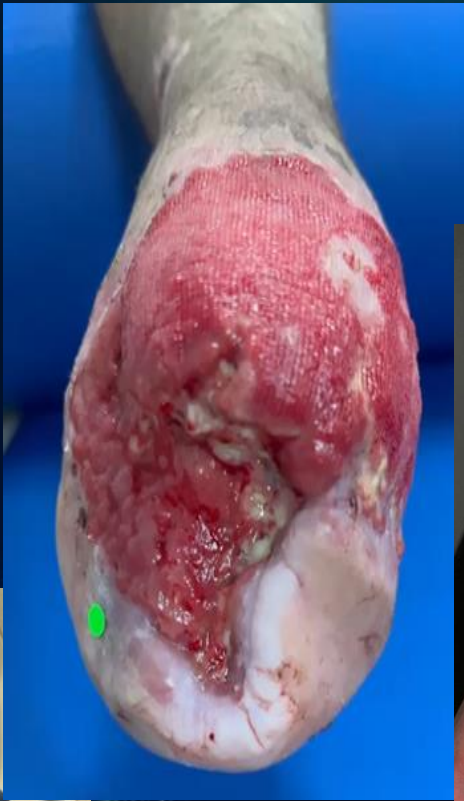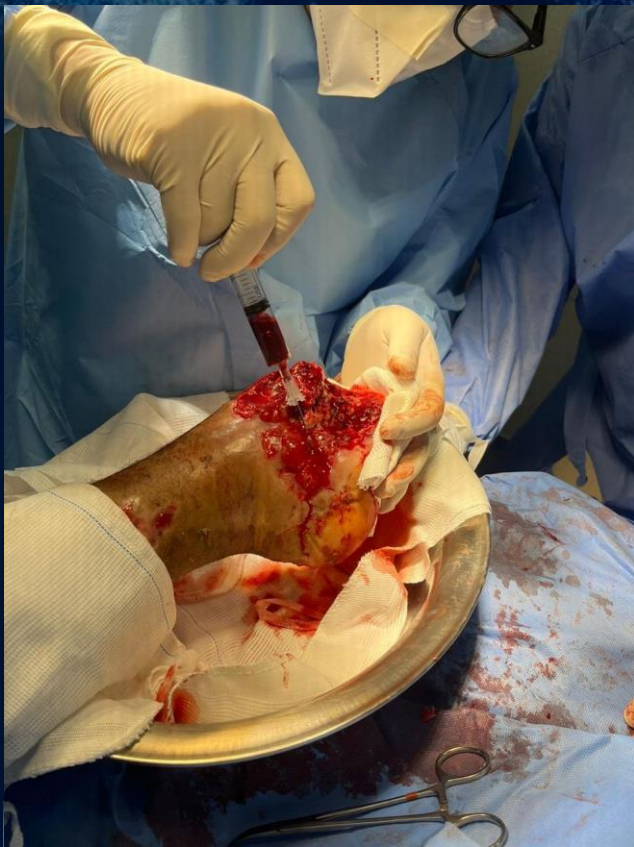BMA

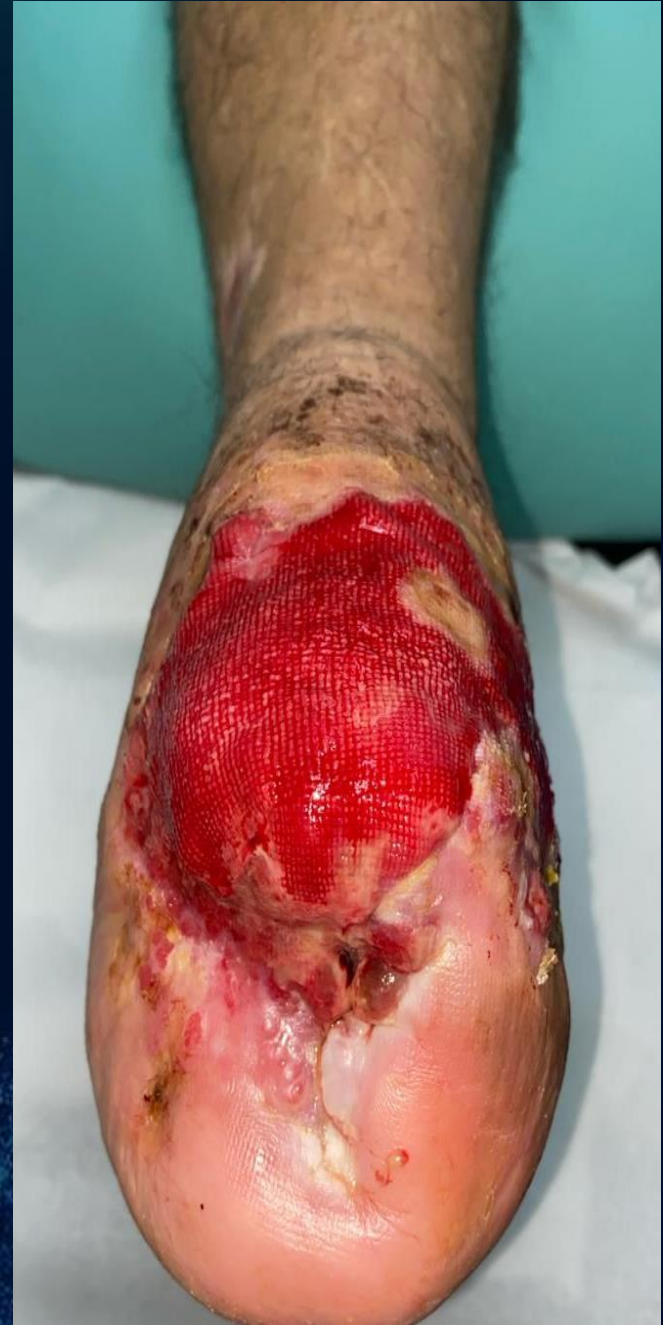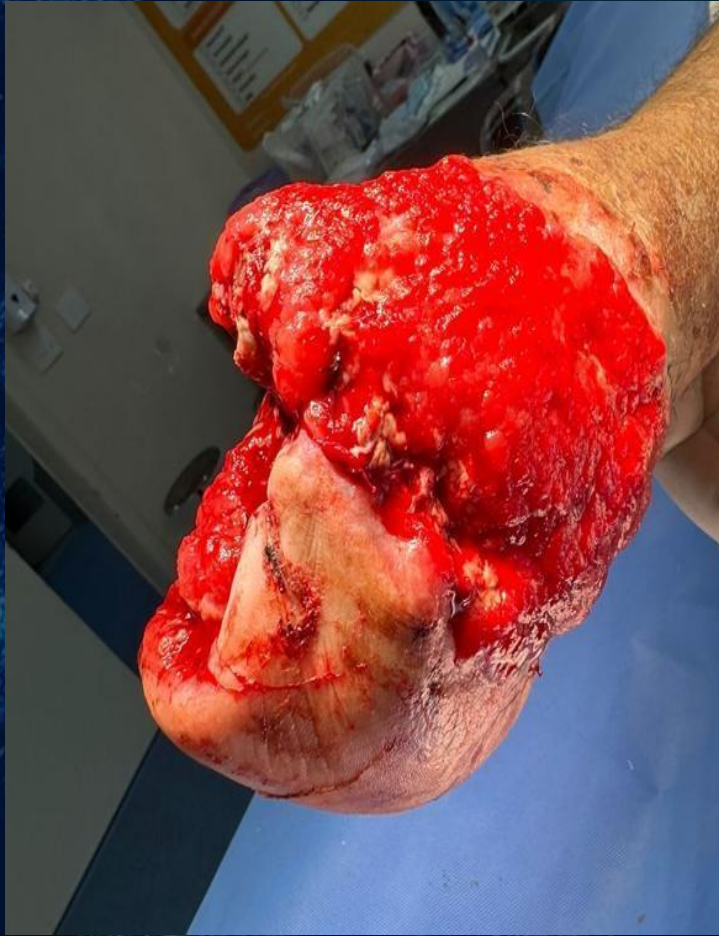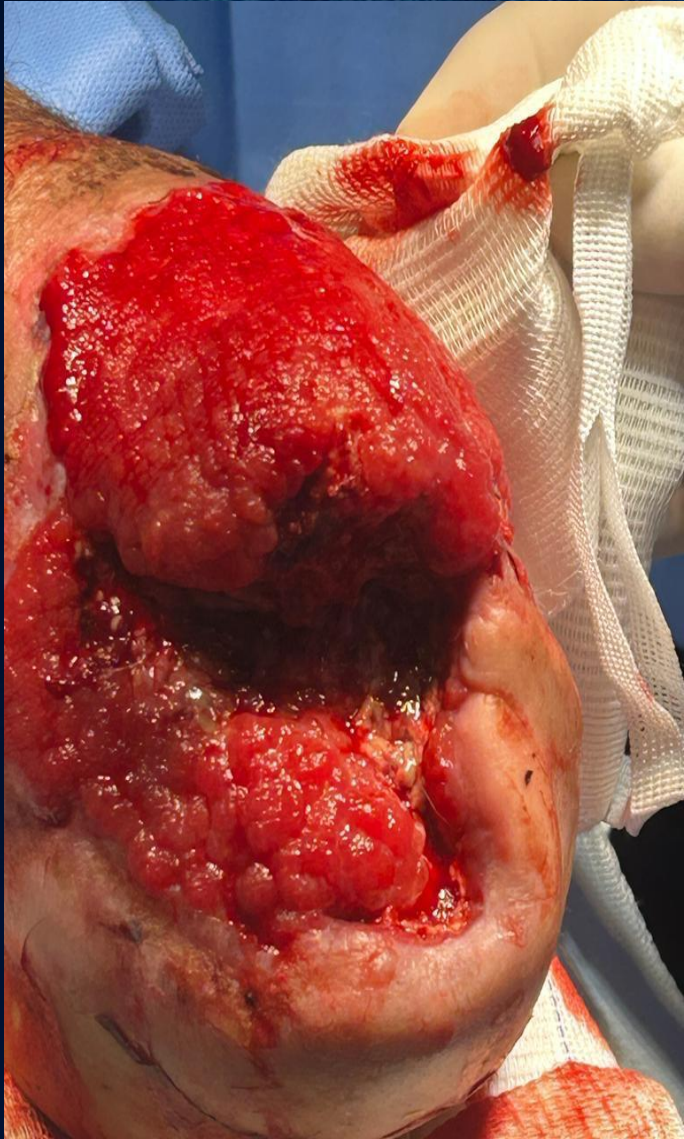Hyperbaric Oxygen Therapy

Physiotherapy and referral to plastic surgery









OUR ADVISORS

KEY OPINION LEADERS IN WOUND CARE



Klaus Kirketerp
Orthopaedic Surgeon

Care Advantage, a
wound clinics based in

Surgeon at Copenhagen Wound Healing Center,
Denmark. His area of research includes infection
and microbiological biofilm.



Eliud Garcia Duarte
Vascular surgeon

Coordinator of the National Commission on
Diabetes and Diabetic Foot for the Brazilian
Society of Angiology and Vascular Surgery.



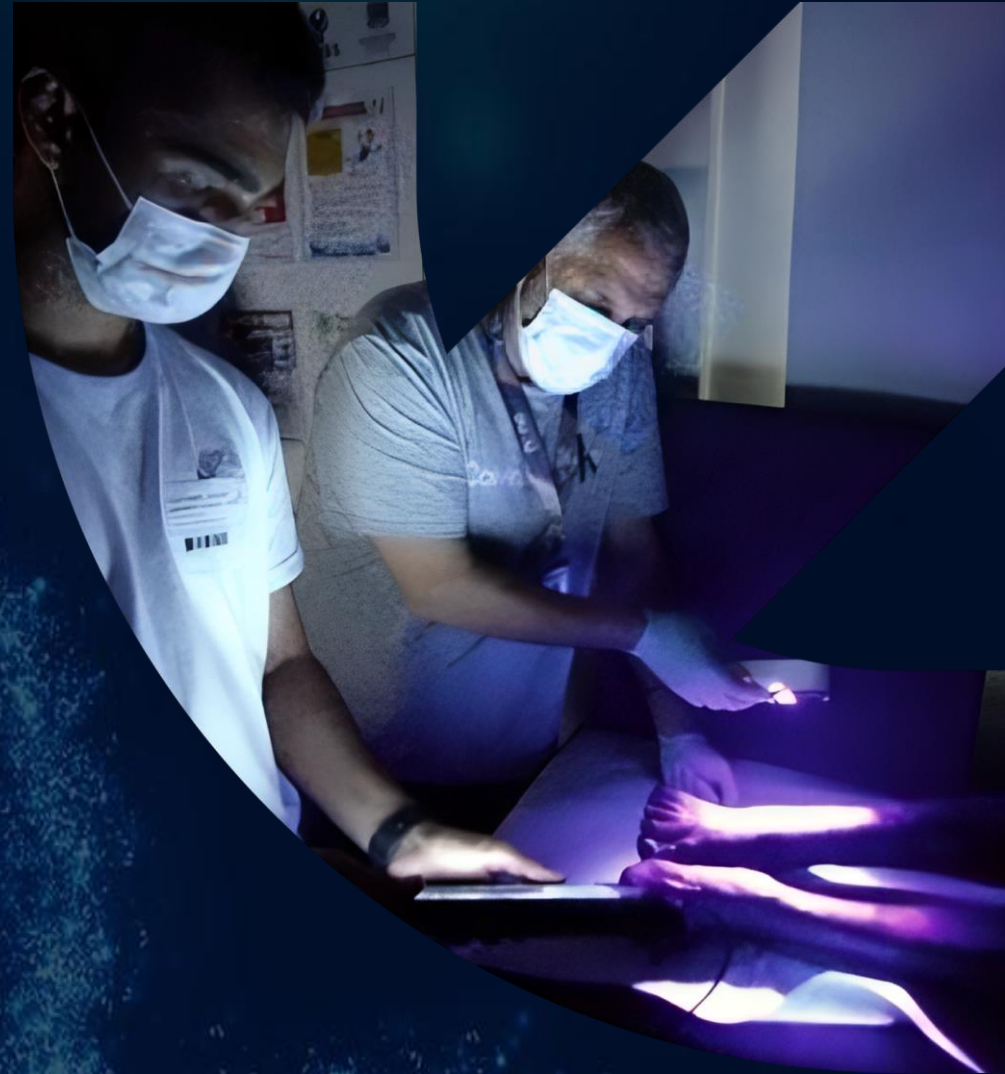Henrik J. Nielsen
Director EWMA

Director of European Wound Management
Association who work on improving wound care
across Europe.



BIOLUMINESCENCE IN PROGRAMMING SURGICAL.

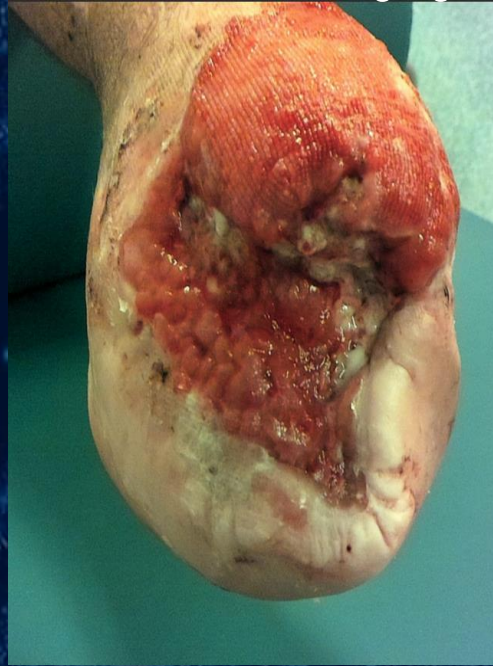
MIMR Optics as a monitoring and tool for the early
detection of infections.



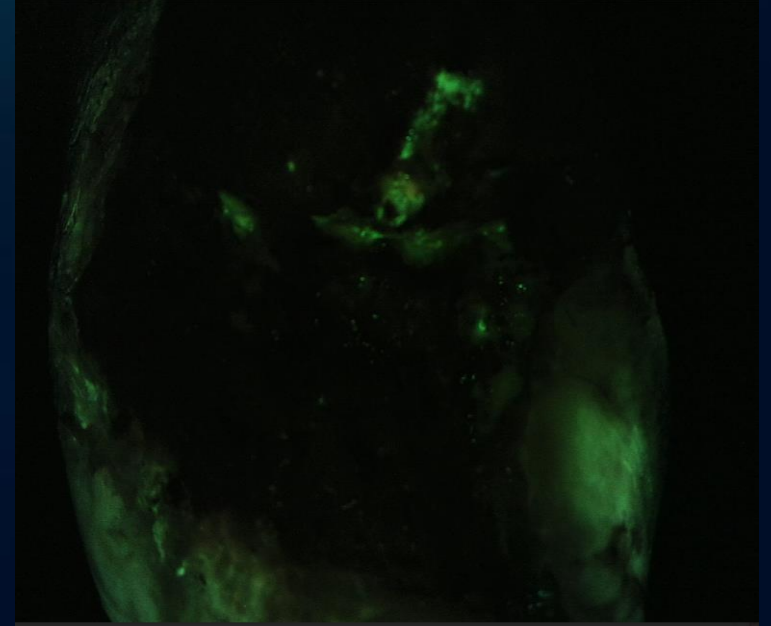
Thermal Imaging



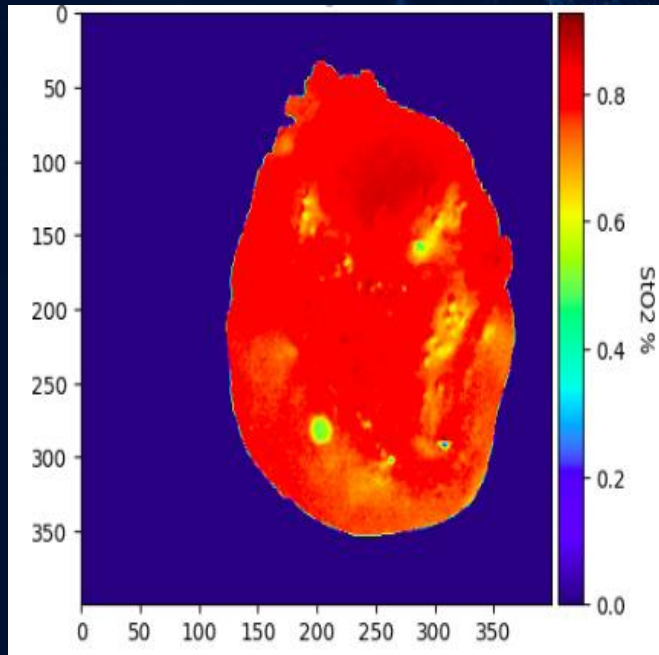
Standard Imaging



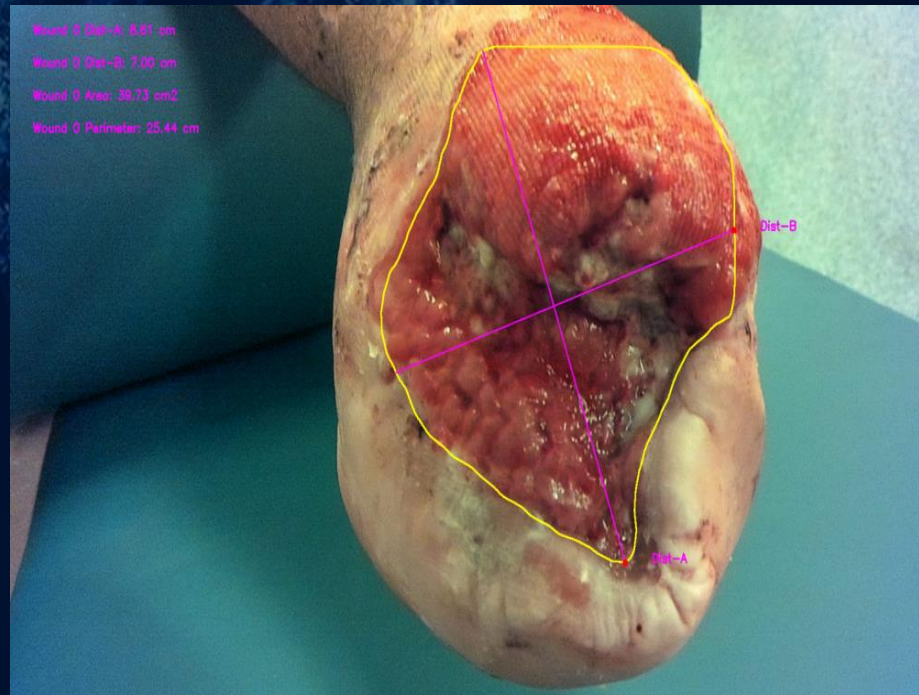
Bioluminescence Imaging



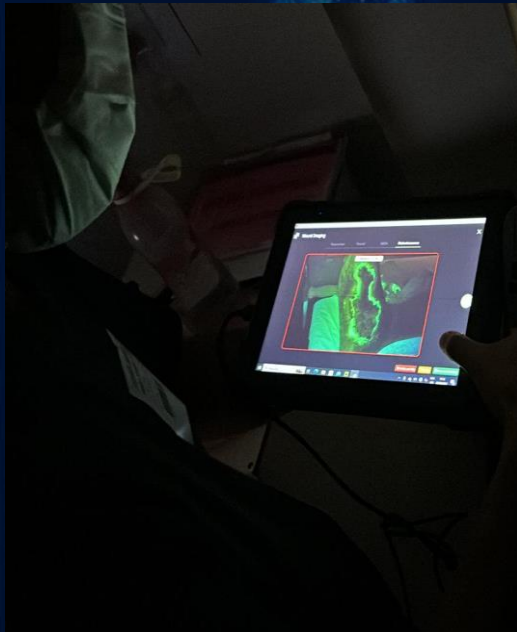
Surface Oxygen Saturation

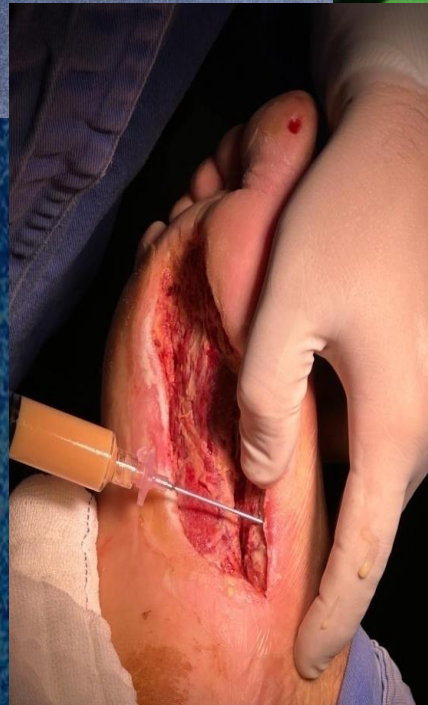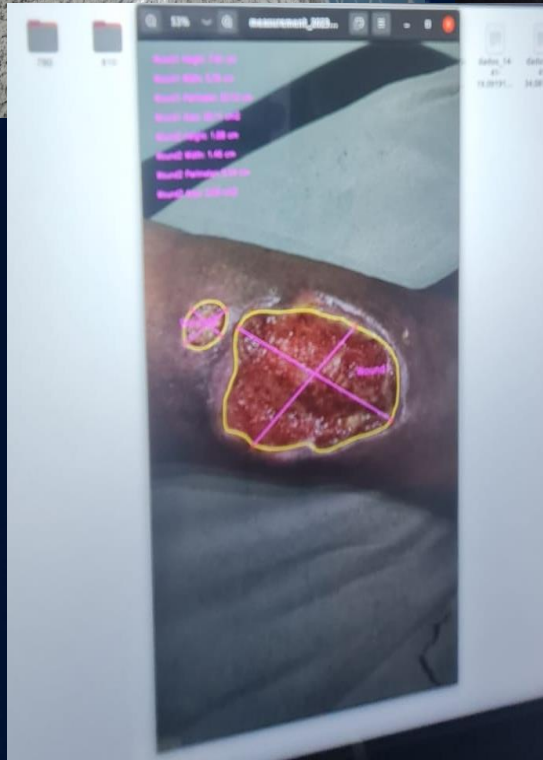
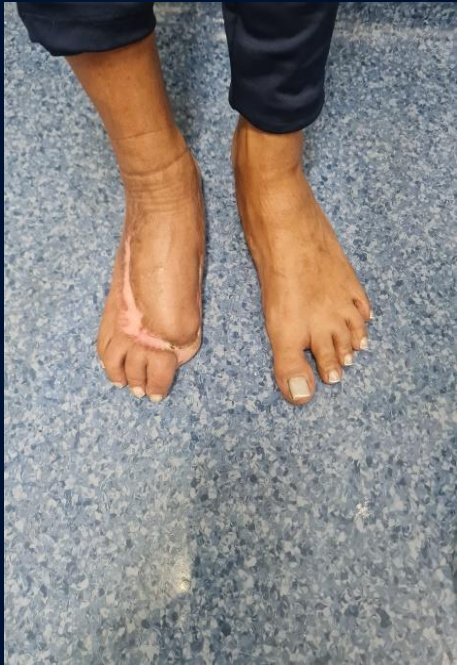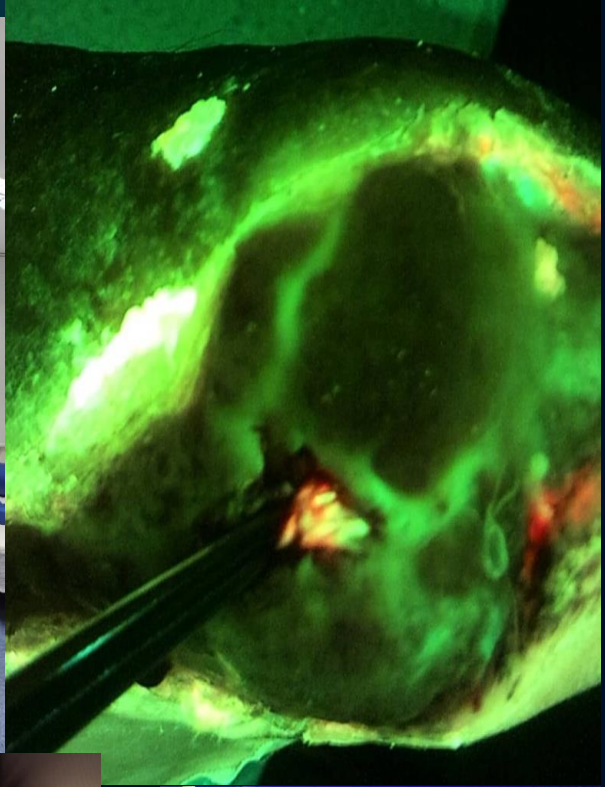


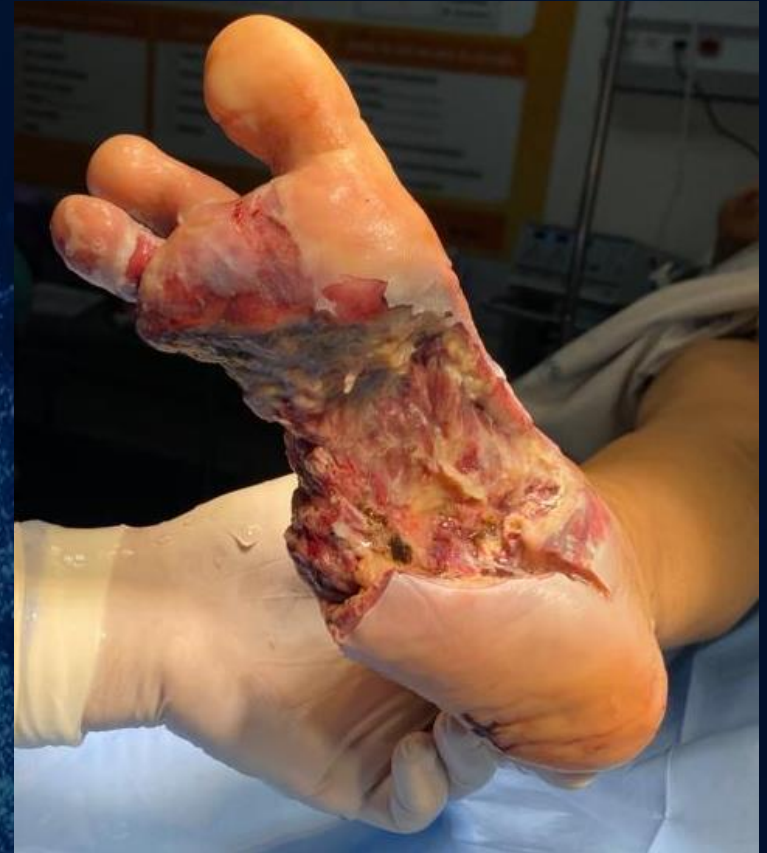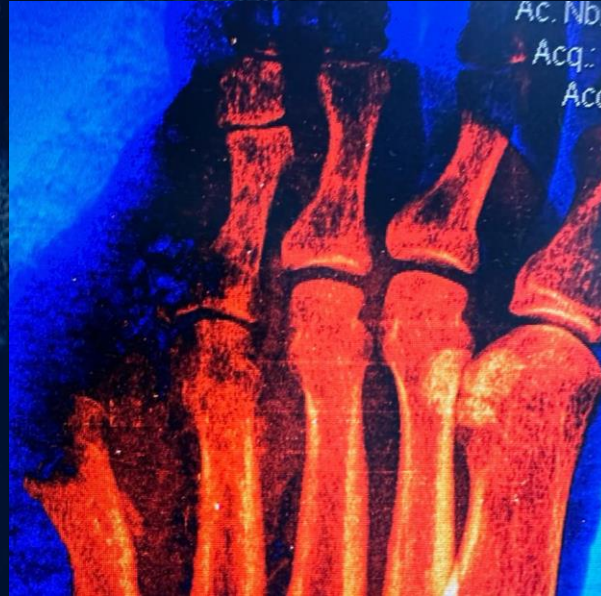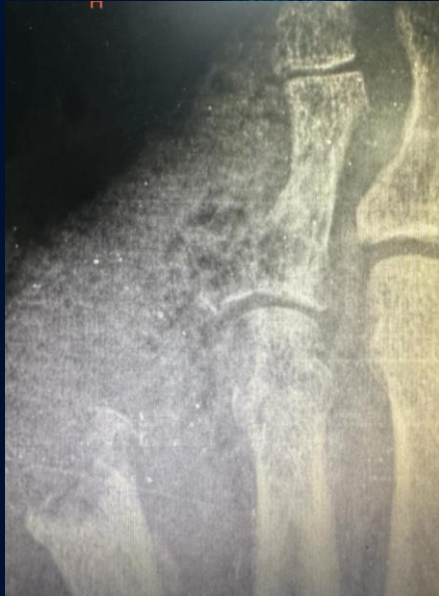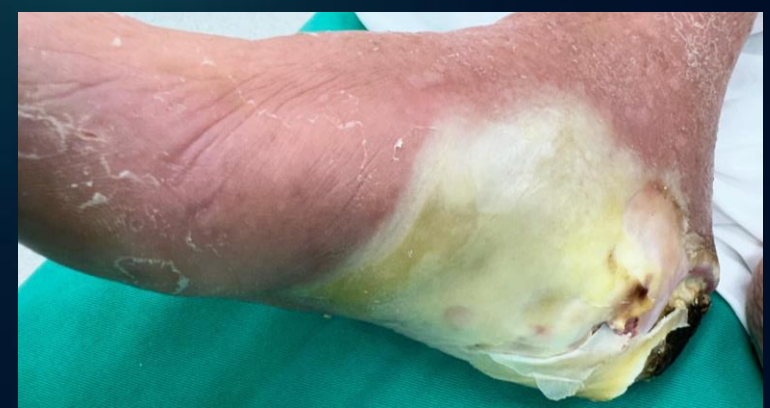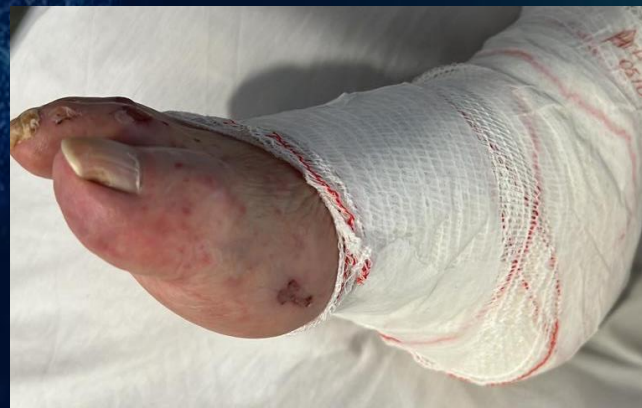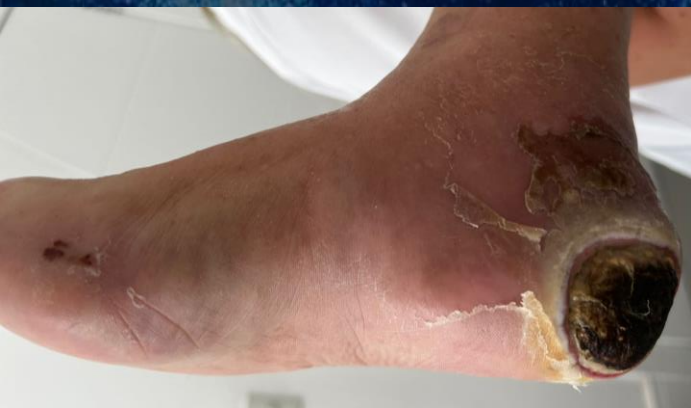Automatic Wound Measurement



Bioluminescence



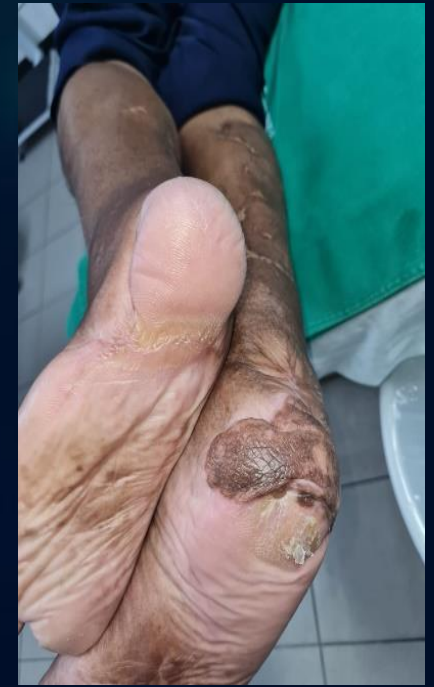
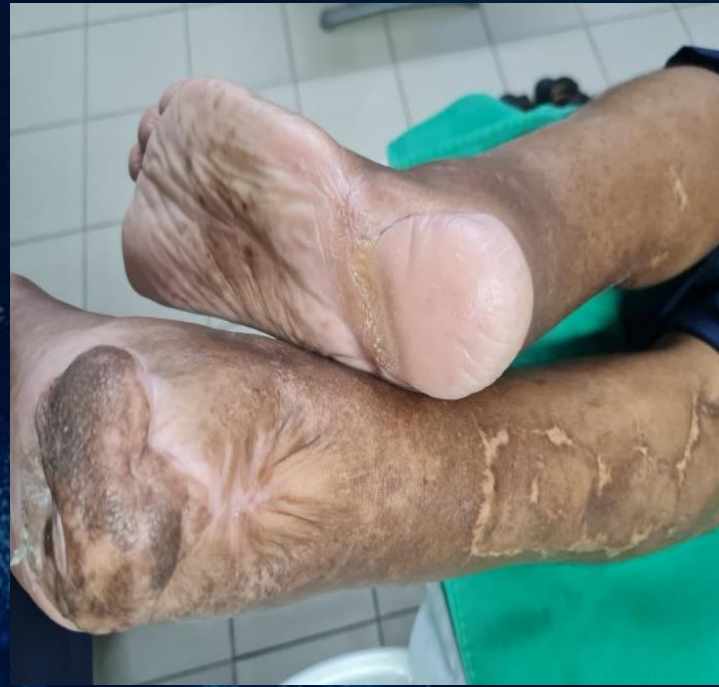
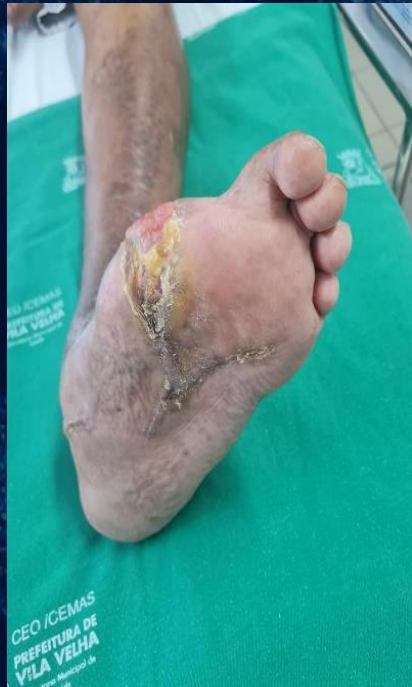
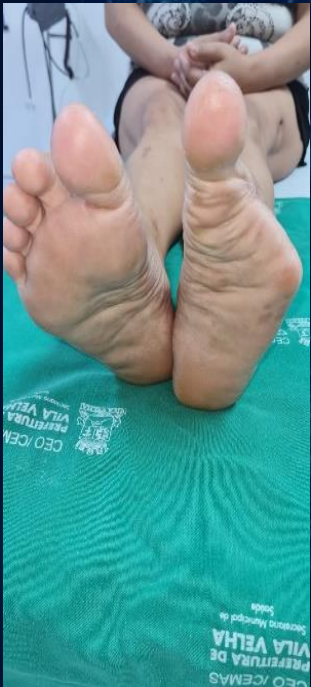
“There are three paths to failure.”

Beda

Philosopher



*"Teaching what you know - mental generosity
Practice what is taught - ethical coherence
Ask what is ignored - intellectual humility."*

Mario Sérgio Cortella
Filósofo



CONSELHO FEDERAL DE MEDICINA

PORTARIA CFM N.º. SEI-147/2023

O **PRESIDENTE DO CONSELHO FEDERAL DE MEDICINA**, no uso das atribuições que lhe confere a Lei n.º 3.268, de 30 de julho de 1957, com alterações da Lei n.º 11.000, de 15 de dezembro de 2004, regulamentada pelo Decreto n.º 44.045, de 19 de julho de 1958, alterado pelo Decreto n.º 10.911, de 22 de dezembro de 2021, e o artigo 24 da Resolução CFM n.º 1998, de 10 de agosto de 2012, que aprova o Regimento Interno do CFM e conforme ato do Presidente em 01 de agosto de 2023.

RESOLVE:

Art. 1º Incluir o **Dr. Eliud Garcia Duarte Junior** no **Grupo de Trabalho sobre questões relacionadas ao pé diabético**, que passará a ter a seguinte composição:

- Alexandre Fiorini Gomes - Convidado CFM
- **Annelise Mota de Alencar Meneguesso - CFM (Coordenadora)**
- Antônio Carlos de Souza - Convidado CFM
- Eliud Garcia Duarte Junior - Convidado CFM
- Guilherme Benjamin Brandão Pitta - SBACV
- Leonardo Cançado Monteiro Savassi - Convidado CFM
- Melanie Rodacki - Convidada CFM

Art. 2º Revogam-se todas as disposições em contrário.

Art. 3º Esta Portaria entra em vigor na data de sua assinatura.

Brasília, 01 de agosto de 2023

DIABETIC FOOT COURSE

ADVANCED DIABETIC FOOT SUPPORT

A.D.F.S.[®]

TECNOVASC2022



I Congresso Brasileiro de Medicina Vascular Regenerativa

TECNOVASC

AGOSTO AZUL VERMELHO
MÊS DE CONSCIENTIZAÇÃO À SAÚDE VASCULAR

MEDICINA REGENERATIVA EM CIRURGIA VASCULAR

DIRETORIA BIÊNIO 2022-2023
PRESIDENTE:
ELIUD GARCIA DUARTE JUNIOR

AUTORES:
CICERO FIDELIS
ELIUD GARCIA DUARTE JUNIOR
MARITA VON RAUTENFELD
MARCO TEIXEIRA
MICHAEL CHILDS
RINA MARIA PEREIRA PORTA
SERGIO BELCZAK
SERGIO TIOSSI

ORTHO REGEN
International Courses

CÉLULAS-TRONCO MEDICINAIS



 EDIÇÃO BRASILEIRA

José Fabio Lana

Anna Vitória Lana *In Memoriam*

André Pinto Lemos de Faria

André Vinicius Sauressig Kruehl

Annu Navani

Ansar Mahmood

Daniel de Moraes Ferreira Jorge

Eduardo Fonseca Vicente

Gabriel Ohana Marques Azzini

Ignacio Dallo

Joseph R. Purita

João Vitor Lana

Carolina Caliarri Oliveira

Lucas Furtado da Fonseca

Lucas Leite Ribeiro

Luyddy Pires

Marita von Rautenfeld

Napoliane Santos

Peter A. Everts

Rafael Barnabé Domingues

Stephany Cares Huber

Tomas Mosaner de Souza Moraes

Edição 2024



Brasil Sustentável Editora



AGOSTO AZUL VERMELHO VASCULAR

VIRTUAL BOOK - SBACV-ES

Diretoria Biênio 2020-2021
Presidente: Eliud Garcia Duarte Junior

ATUAÇÃO MULTI E INTERDISCIPLINAR NA SÍNDROME DO PÉ DIABÉTICO: REDUZINDO MUTILAÇÕES

Coordenação:
Dr. Eliud Garcia Duarte Junior- ES
Dr. Michael Childs - EUA
Dr. Cicero Fidelis - BA




- Complex Regenerative Therapies cases performed and under follow-up in the service n=85



PEZÃO NA ROÇA

@pezaonarocaoficial

**NATUREZA,
LAZER E
GASTRONÔMIA**




SETUP
VASCULAR SYMPOSIUM

26 a 28 de junho de 2024 | São Paulo-SP



medical
soft skills



medicina
regenerativa



VENOSAN[®]
Compression Course




Flebo
SETUP

CURSO



medical
COURSE



ENDOASCULAR
ACADEMY

Medtronic

<https://setupvascular.com.br/>

EDUCAÇÃO FINANCEIRA
CEFIM 2024
PARA MÉDICOS

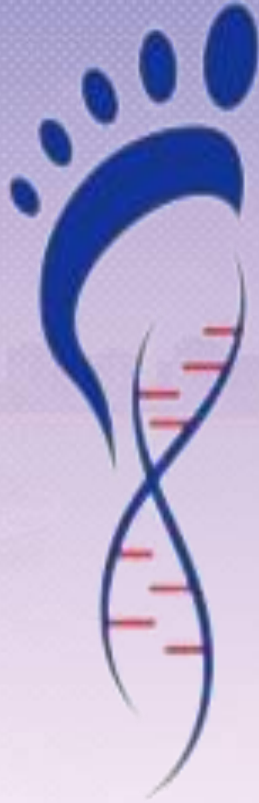

6th Edition

INTERNATIONAL
CONGRESS OF
**REGENERATIVE
MEDICINE**



ORTHO REGEN
International Course



Thank you

Eliud Duarte

INSTITUTE

Angiology, Vascular Surgery, and Regenerative
Medicine

Tel: +55 27 999432208

E-mail: dreliudvascular@gmail.com

